

Thrombolysis in Brain Ischemia (TIBI) Transcranial Doppler Flow Grades Predict Clinical Severity, Early Recovery, and Mortality in Patients Treated With Intravenous Tissue Plasminogen Activator

Andrew M. Demchuk, W. Scott Burgin, Ioannis Christou, Robert A. Felberg, Philip A. Barber, Michael D. Hill and Andrei V. Alexandrov

Stroke. 2001;32:89-93

doi: 10.1161/01.STR.32.1.89

Stroke is published by the American Heart Association, 7272 Greenville Avenue, Dallas, TX 75231

Copyright © 2001 American Heart Association, Inc. All rights reserved.

Print ISSN: 0039-2499. Online ISSN: 1524-4628

The online version of this article, along with updated information and services, is located on the World Wide Web at:

<http://stroke.ahajournals.org/content/32/1/89>

Permissions: Requests for permissions to reproduce figures, tables, or portions of articles originally published in *Stroke* can be obtained via RightsLink, a service of the Copyright Clearance Center, not the Editorial Office. Once the online version of the published article for which permission is being requested is located, click Request Permissions in the middle column of the Web page under Services. Further information about this process is available in the [Permissions and Rights Question and Answer](#) document.

Reprints: Information about reprints can be found online at:
<http://www.lww.com/reprints>

Subscriptions: Information about subscribing to *Stroke* is online at:
<http://stroke.ahajournals.org/subscriptions/>

Thrombolysis in Brain Ischemia (TIBI) Transcranial Doppler Flow Grades Predict Clinical Severity, Early Recovery, and Mortality in Patients Treated With Intravenous Tissue Plasminogen Activator

Andrew M. Demchuk, MD, FRCPC; W. Scott Burgin, MD; Ioannis Christou, MD;
Robert A. Felberg, MD; Philip A. Barber, MB, ChB, MRCP;
Michael D. Hill, MD, FRCPC; Andrei V. Alexandrov, MD

Background and Purpose—TIMI angiographic classification measures coronary residual flow and recanalization. We developed a Thrombolysis in Brain Ischemia (TIBI) classification by using transcranial Doppler (TCD) to noninvasively monitor intracranial vessel residual flow signals. We examined whether the emergent TCD TIBI classification correlated with stroke severity and outcome in patients treated with intravenously administered tPA (IV-tPA).

Methods—TCD examination occurred acutely and on day 2. TIBI flows were determined at distal MCA and basilar artery depths, depending on occlusion site. TIBI waveforms were graded as follows: 0, absent; 1, minimal; 2, blunted; 3, dampened; 4, stenotic; and 5, normal. National Institutes of Health Stroke Scale (NIHSS) scores were obtained at baseline and 24 hours after administration of tPA.

Results—One hundred nine IV tPA patients were studied. Mean \pm SD age was 68 ± 16 years; median NIHSS score before administration of tPA (pre-tPA) was 17.5. The tPA bolus was administered 143 ± 58 minutes and the TCD examination 141 ± 57 minutes after symptom onset. Pre-tPA NIHSS scores were higher in patients with TIBI grade 0 than TIBI grade 4 or 5 flow. TIBI flow improvement to grade 4 or 5 occurred in 35% of patients (19/54) with an initial grade of 0 or 1 and in 52% (12/23) with initial grade 2 or 3. The 24-hour NIHSS scores were higher in follow-up in patients with TIBI grade 0 or 1 than those with TIBI grade 4 or 5 flow. TIBI flow recovery correlated with NIHSS score improvement. Lack of flow recovery predicted worsening or no improvement. In-hospital mortality was 71% (5/7) for patients with posterior circulation occlusions; it was 22% (11/51) for patients with pre-tPA TIBI 0 or 1 compared with 5% (1/19) for those with pre-tPA TIBI 2 or 3 anterior circulation occlusions.

Conclusions—Emergent TCD TIBI classification correlates with initial stroke severity, clinical recovery, and mortality in IV-tPA-treated stroke patients. A flow-grade improvement correlated with clinical improvement. (*Stroke*. 2001;32:89-93.)

Key Words: stroke, acute ■ thrombolysis ■ ultrasound ■ ultrasonography, Doppler, transcranial

Clinical benefit of tissue plasminogen activator (tPA) in ischemic stroke is linked to accelerated clot lysis and early recanalization.^{1,2} However, previous angiographic studies³ with systemic tPA in stroke have revealed only a 30% to 40% recanalization rate. Cardiology studies⁴ suggest that circulation to and about the thrombus appears to be the most important factor associated with thrombolytic failure. Persisting perfusion or residual flow around coronary arteries is best measured angiographically and can be graded with the thrombolysis in myocardial ischemia (TIMI) flow grades.⁵ Such a grading system has not been established for intracranial vessels. Transcranial Doppler (TCD) is the ideal nonin-

vasive, real-time bedside tool for evaluation of cerebral vessels, particularly in the setting of thrombolysis. We sought to develop a grading system for residual flow with use of TCD. This study describes and evaluates a novel TCD grading system for residual flow called Thrombolysis in Brain Ischemia (TIBI; Health Outcomes Institute, Inc) in a series of systemically treated acute stroke patients.

Subjects and Methods

Using a standard TCD protocol, we prospectively evaluated patients who received intravenous tPA (IV-tPA) in the emergency room.⁶ An experienced sonographer used single-channel 2-MHz TCD (Mul-

Received June 16, 2000; final revision received August 22, 2000; September 5, 2000.

From the Seaman Family MR Research Centre, Department of Clinical Neurosciences, University of Calgary, Calgary, Canada (A.M.D., P.A.B., M.D.H.), and Center for Noninvasive Brain Perfusion Studies, Stroke Program, Department of Neurology, University of Texas-Houston (A.M.D., W.S.B., I.C., R.A.F., A.V.A.).

Correspondence to Dr Andrew M. Demchuk, Seaman Family MR Research Centre, Department of Clinical Neurosciences, University of Calgary, 1403 29 St NW, Calgary AB, Canada T2N 2T9. E-mail ademchuk@dcns.ucalgary.ca

© 2001 American Heart Association, Inc.

Stroke is available at <http://www.strokeaha.org>

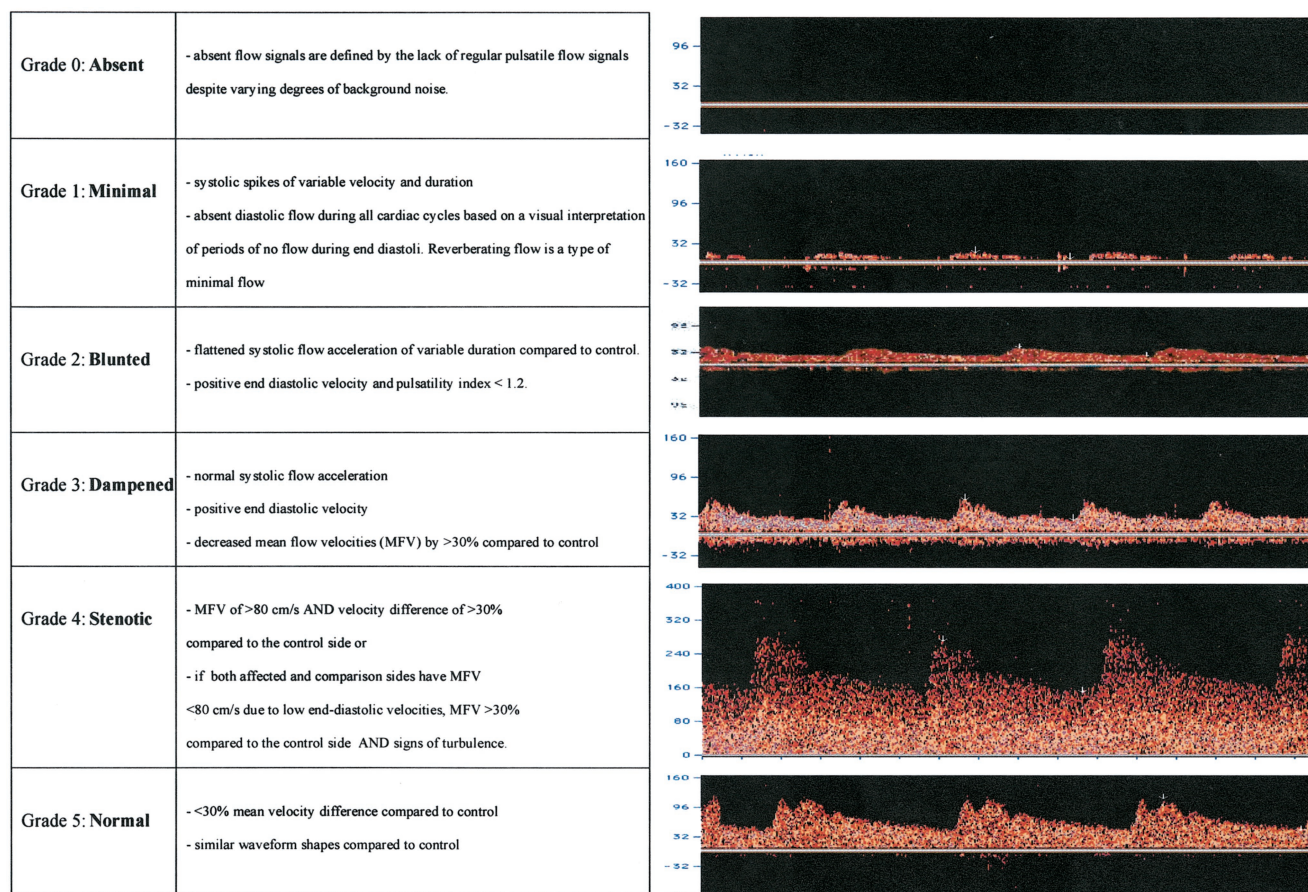


Figure 1. Description and illustration of the TIBI residual flow classification (grades 0 through 5).

tigon 500M; Multi-Dop-T, DWL/Neuroscan; Neuroguard, Medasonics/Nicolet; and Marc series headframe, Spencer Technologies). TCD examination was performed in each instance at the earliest time possible during initial stroke evaluation. No delay in tPA administration was experienced because of TCD examination. tPA was given intravenously within the first 3 hours after stroke onset at a standard dose of 0.9 mg/kg, following the NINDS tPA guidelines in most cases.⁷ In 11 cases a reduced dose of 0.6 mg/kg was given intravenously and followed by intra-arterial thrombolysis as part of an experimental, nonrandomized pilot protocol for patients beyond the 3-hour time window. Arterial occlusion was identified at pre-tPA TCD using a standard set of diagnostic criteria previously validated by the investigators.⁸ Residual flow signals were identified at the most distal part of the affected vessel, with depths of insonation being specific to the presumed occlusion site on TCD. For the purposes of this study, residual flow signals were recorded at the distal middle cerebral artery (MCA) or basilar artery (BA).

In patients with evidence of anterior circulation occlusion (internal carotid artery [ICA], MCA, or both), TIBI flow grade was determined via a transtemporal window at a depth of ≤ 54 mm, corresponding to the distal MCA arterial bed. In patients with evidence of posterior circulation occlusion (vertebral artery or BA), TIBI flow grade was determined through the transforaminal window at depth of 80 to 100 mm, corresponding to BA stem location. For the purposes of this study, the worst flow signal determined at the presumed occlusion site was analyzed.

The 2 centers adopted similar approaches to performing and interpreting the TCD examinations. At both sites, a stroke neurologist performed the TCD study and interpreted the results immediately. At the Calgary site, a stroke nurse coordinator also was trained in TCD examination and performed some of the studies. Houston

neurosonographers were generally more experienced than the Calgary counterparts with TCD examination.

The TIBI residual flow classification consists of 6 grades. The individual flow grades are described and illustrated in Figure 1.

Patient age, sex, and baseline stroke severity (using the National Institutes of Health Stroke Scale [NIHSS] score) were prospectively collected on all patients. A follow-up NIHSS score was obtained at 24 hours after stroke onset. A follow-up TCD was repeated several hours after tPA infusion, usually the following day. All intracranial hemorrhages, including symptomatic intracerebral hemorrhage, were identified on the basis of review of the follow-up CT. In-hospital mortality was determined prospectively.

Patients' NIHSS scores were grouped according to their TIBI grade, and mean scores were compared, by group, with the Kruskal-Wallis test. Trends were assessed by using the Wilcoxon rank sum extension method of Cuzick.⁹ Improvement was assessed by categorizing the change from baseline to 24-hour NIHSS score as ≤ 5 or ≥ 5 and by categorizing the improvement in TIBI grade as true or false. All comparisons of proportions were done with the Fisher exact test.

Results

A total of 109 patients treated with intravenous tPA between November 1996 and April 2000 were studied by emergent TCD examination at 2 institutions: University of Texas–Houston (85 patients) and University of Calgary (24 patients). Fifteen patients were excluded from analysis (8 because of inadequate temporal bone windows, 5 because TCD was performed >2 hours after tPA treatment, and 2 because of

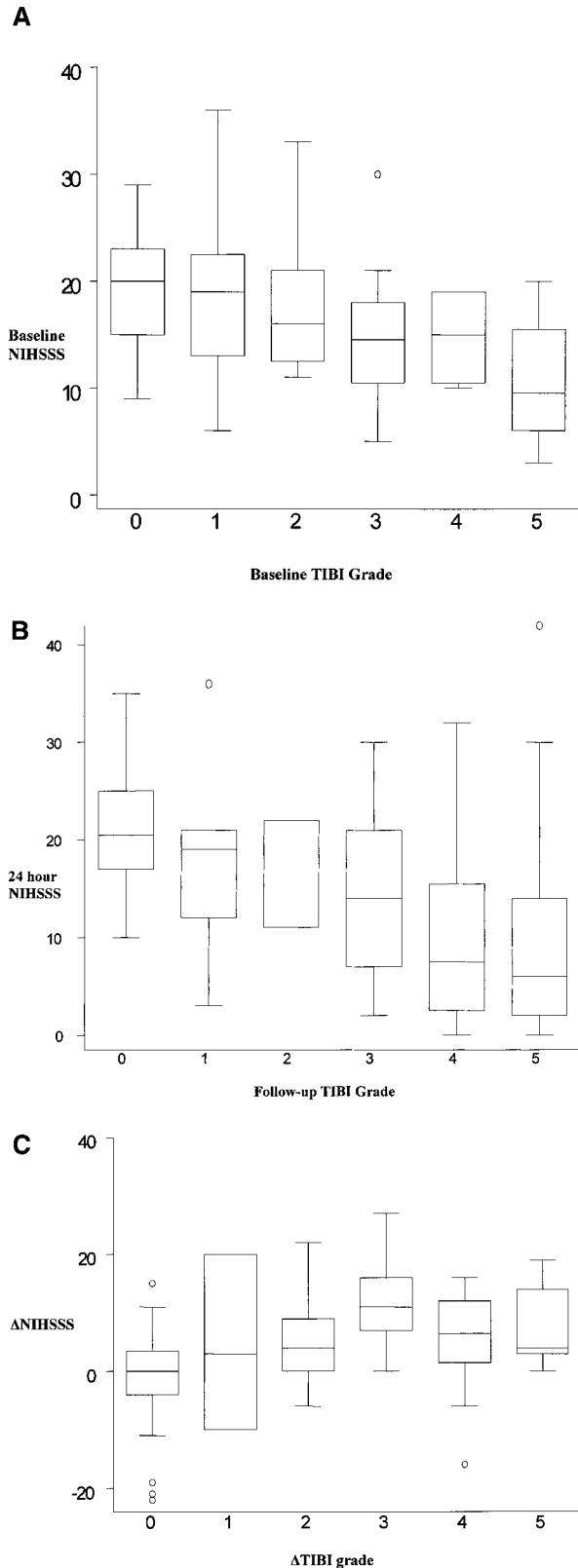


Figure 2. A, Baseline NIHSS scores based on initial TIBI flow grades; B, 24-hour NIHSS scores based on follow-up TIBI flow grades; and C, correlation between 24-hour improvement of NIHSS scores and TIBI flow grade recovery.

Effects on Clinical Status Based on TIBI Flow Change

Initial TIBI Grade→ Follow-Up TIBI Grade	n	Median Δ NIHSS Score
Flow deterioration		
2-3→0-1	1	+10
No change		
0-1→0-1	18	0
2-3→2-3	10	0
4-5→4-5	16	-2
Flow improvement		
0-1→2-3	14	-5
0-1→4-5	21	-6
2-3→4-5	12	-9.5

missing data on the timing of TCD examination). Of the 94 patients analyzed, emergent TCD examination identified 69 MCA occlusions (73%), 22 ICA occlusions (23%), 20 multiple-vessel occlusions (21%), 7 BA occlusions (7%), and 1 vertebral artery occlusion (1%). Sixteen patients (17%) had no identifiable occlusion. The patients' mean±SD age was 68±16 years, and the median pre-tPA NIHSS score was 17.5. The tPA bolus was given at 143±58 minutes and the TCD examination at 141±57 minutes after stroke onset. Of the 22 TCD studies performed after administration of the tPA bolus, only 5 were performed >30 minutes after the start of the bolus. Seventy-five TCD studies were performed within 20 minutes before or after the tPA bolus. Sixteen of the 94 patients were treated with intravenous tPA >3 hours after symptom onset. TCD was performed a median of 6 minutes before tPA bolus administration in Houston and a median of 11 minutes after bolus administration in Calgary. The rate of anterior circulation occlusion was higher in Houston (59/73; 82%) than in Calgary (12/21; 57%). Baseline NIHSS scores were slightly higher in Houston than Calgary (median NIHSS score of 18 versus 15, respectively).

Baseline NIHSS scores were strongly associated with baseline TIBI grades ($P=0.004$; Figure 2A). The 24-hour NIHSS scores were strongly associated with follow up TIBI grades ($P=0.002$) (Figure 2B). Similarly strong trends were observed with increasing NIHSS scores associated with poorer TIBI flow grades at both the baseline and 24-hour time points ($P<0.001$).

TIBI flow improvement to grades 4 or 5 occurred in 35% of patients (19/54) with an initial grade of 0 or 1 and 52% (12/23) with initial grade 2 or 3. No patient with an initial TIBI grade of 4 or 5 deteriorated in flow grade. Flow-grade improvement occurred in 2 of 2 isolated ICA occlusions, 22 of 49 isolated MCA occlusions (45%), and only 4 of 20 tandem ICA/MCA occlusions (20%).

The change in TIBI flow grade between baseline and follow-up examinations was significantly associated with change in NIHSS score ($P<0.001$) (Figure 2C). Improvement by baseline TIBI category is shown in the Table. Flow that did not improve was matched with little or not improvement in the NIHSS score at 24 h.

In-hospital mortality was 71% (5/7) for posterior circulation occlusion and 17% (12/70) for anterior circulation

occlusion (Fisher exact test, $P=0.005$). Among anterior circulation occlusions, there was 22% mortality (11/51) in patients with baseline TIBI grades 0 or 1 and 5.3% (1/19) in those with baseline grades 2 or 3. Symptomatic intracerebral hemorrhage occurred in 6 patients (6.4%). Among patients who suffered symptomatic ICH, 3 had poor flow (baseline TIBI grade 1 to 3) and 3 had good flow (baseline grade 4 to 5). Of 4 patients who died of symptomatic hemorrhage, 3 had baseline TIBI grade 4 or 5 flow. However, 1 of these patients died of a remote hemorrhage into the brain stem rather than into the area of MCA ischemia.

Discussion

The TIBI flow grades represent the first systematic classification of residual flow determined by TCD for major intracranial vessels. Although TCD measurements cannot be used to calculate flow volume,¹⁰ our study shows that TIBI flow grades can be used to quantitate residual flow appearance and its relationship to stroke severity. Because flow-grade improvement is associated with early recovery, our findings support the hypothesis developed in cardiology that residual flow predicts success of thrombolytic therapy. In our study, tPA-treated patients with higher TIBI flow grades were more likely to achieve flow recovery. No improvement in the residual flow as determined by TIBI also correlated with lack of early recovery and mortality.

Vascular imaging is currently lacking in the standard emergent evaluation of acute stroke. Critics of the across-the-board use of systemic tPA suggest that vascular imaging is needed to better identify patients who will and will not benefit from this treatment.¹¹ Several studies^{12,13} have previously shown that TCD findings in the setting of acute stroke have utility through their prediction of clinical outcome. Patients with acutely normal TCD results appear to have favorable prognosis.¹⁴ An abnormal TCD study, defined as no or asymmetrical MCA flow signal, is associated with poor outcome.¹⁵ Development of the TIBI classification is an extension of previous work that examined the potential value of TCD as a vascular study for acute stroke, particularly in the setting of thrombolytic treatment.^{6,16} We have previously developed diagnostic TCD criteria for each site of arterial occlusion and recanalization that is accurate and correlates with angiographic occlusion and recanalization.^{7,17}

Because mortality was significantly higher in patients with a poor TIBI grade at baseline, the TIBI grading system may be prognostically useful early in the course of hospitalization. Equally, the group with very poor TIBI grades (TIBI 0 and 1) may be an ideal target for additional intra-arterial thrombolytic or mechanical interventions. Similarly, the change in TIBI flow from baseline to follow-up may aid physicians in providing an early assessment of outcome and facilitating disposition planning.

A surprising and alarming finding of this study was that was 3 symptomatic intracerebral hemorrhages occurred in patients with normal baseline TIBI flow grades (25% symptomatic ICH rate among initial TIBI grade 5 patients). This finding raises the question of whether tPA could be harmful in a setting of “freshly” reperfused brain. Recent animal studies^{18,19} have suggested that alteplase may enhance blood-

brain barrier disruption. An animal study²⁰ of embolic focal cerebral ischemia revealed a significant increase in hemorrhage volumes when tPA was administered at the time of late mechanical reperfusion compared with no hemorrhage with late mechanical reperfusion alone. Further scrutiny of this subgroup of patients is needed to understand whether alteplase benefits patients with open arteries and “stunned brain” and whether alteplase increases the risk of hemorrhage.

There are potential limitations of the TIBI classification. First, TIBI grade 0 (or absent flow) could have been inappropriately concluded because of technical problems, such as inadequate bony windows, inconsistent technical skill, or absence of imaging control with TCD. We feel that this source of error was minimized by the considerable effort that was made in each instance to find the bony window. In most cases, a good posterior cerebral artery waveform or proximal MCA/anterior cerebral artery waveforms were identified to ensure that a good window had been identified. The second limitation is that TIBI flow grades were not compared with gold-standard imaging techniques that may visualize residual flow. Studies are required to evaluate the relationship between TIBI grades and gold-standard imaging, such as high-resolution contrast angiography. Our group has utilized aspects of the TIBI classification to develop TCD criteria for recanalization. With use of these criteria, TCD has excellent correlation with angiography for complete recanalization (sensitivity 91%, specificity 93%).¹⁷ (The number of tPA patients also undergoing angiography was too small to include in this study.)

The third limitation is the lack of information regarding importance of TIBI in arterial segments other than those affected by ischemia. TCD can directly insonate proximal vascular structures such as M1 MCA, A1 anterior cerebral artery, and P1-P2 posterior cerebral artery. TCD can only indirectly provide information about more distal vascularity. In this study, only MCA and BA segments were evaluated to concentrate on the perfusion status in the critical brain areas most often affected by ischemia. A further study of the TIBI classification in other proximal arterial segments is needed.

This study introduces a novel TCD flow grading system that is prognostically useful, and a companion paper will describe reliability of the scale. TIBI correlates with clinical deficit, clinical improvement, and mortality in a series of thrombolytically treated stroke patients. An improvement in TIBI flow during TCD monitoring is an important positive predictor. In the future, this scale could be used as an inexpensive, real-time surrogate marker of thrombolytic effectiveness to enable rapid assessment of various thrombolytic treatments and delivery strategies in stroke. We feel the TIBI classification should be incorporated into the standard acute stroke TCD examination and interpretation. The real advantage of TCD is lost if only flow velocity differences are reported and other hemodynamic findings are left behind. TIBI flow grades show information that can be obtained through waveform analysis and provide a convenient way to communicate the results similar to other angiographic scales. After residual flow waveform is identified, this information can be incorporated into TCD interpretation targeted to provide assessment of vessel patency.

Future studies should examine the prognostic role of TIBI flow in patients not receiving thrombolytic therapy. Such a quantitative score, once shown valid and reliable, could have important implications in assisting clinical investigation and treatment of acute stroke.

Acknowledgments

Drs Felberg, Burgin, and Demchuk were supported by National Institutes of Health Fellowship Training Grant 1-T32-NS07412-01A1 for the Stroke Program, University of Texas–Houston. Dr Demchuk is currently supported by the Medical Research Council of Canada and Alberta Heritage Foundation for Medical Research. Dr Christou was supported by the Hellenic Ministry of Defence Visiting Clinician Grant, Athens, Greece. Dr Hill was supported by grants from the Medical Research Council of Canada, the Heart and Stroke Foundation of Canada, and the Alberta Heritage Foundation for Medical Research. The authors would like to acknowledge the assistance of Allison Button in data collection.

References

- Heiss W-D, Grond M, Thiel A, von Stockhausen H-M, Rudolf J, Ghaemi M, Lottgen J, Stenzel C, Pawlik G. Tissue at risk of infarction rescued by early reperfusion: a positron emission tomography study in systemic recombinant tissue plasminogen activator thrombolysis of acute stroke. *J Cereb Blood Flow Metab*. 1998;18:1298–1307.
- Demchuk AM, Felberg RA, Alexandrov AV. Clinical recovery from acute ischemic stroke after early reperfusion of the brain with intravenous thrombolysis. *N Engl J Med*. 1999;340:894–895.
- del Zoppo GJ, Poeck K, Pessin MS, Wolpert SM, Furlan AJ, Ferbert A, Alberts MJ, Zivin JA, Wechsler L, Busse O, Greenlee R, Brass L, Mohr JP, Feldmann E, Hacke W, Kase CS, Biller J, Gress D, Otis SM. Recombinant tissue plasminogen activator in acute thrombotic and embolic stroke. *Ann Neurol*. 1992;32:78–86.
- Anderson JL. Why does thrombolysis fail? Breaking through the reperfusion ceiling. *Am J Cardiol*. 1997;80:1588–1590.
- Hackworthy RA, Sorensen SG, Fitzpatrick PG, Barry WH, Menlove RL, Rothbard RL, Anderson JL. Dependence of assessment of coronary artery reperfusion during acute myocardial infarction on angiographic criteria and interobserver variability. *Am J Cardiol*. 1988;62:538–542.
- Alexandrov AV, Demchuk AM, Wein TH, Grotta JC. Yield of transcranial Doppler in acute cerebral ischemia. *Stroke*. 1999;30:1604–1609.
- The National Institutes of Neurological Disorders and Stroke rt-PA Stroke Study Group. Tissue plasminogen activator for acute ischemic stroke. *N Engl J Med*. 1995;333:1581–1587.
- Demchuk AM, Christou I, Felberg R, Wein T, Malkoff M, Grotta JC, Alexandrov AV. The accuracy and criteria for localizing arterial occlusion with transcranial Doppler. *J Neuroimaging*. 2000;10:1–12.
- Cuzick J. A Wilcoxon-type test for trend. *Stat Med*. 1985;4:87–90.
- Kontos HA. Validity of cerebral arterial blood flow calculations from velocity measurements. *Stroke*. 1989;20:1–3.
- Caplan LR, Mohr JP, Kistler JP, Koroshetz W. Should thrombolytic therapy be the first-line treatment for acute ischemic stroke? Thrombolysis: not a panacea for ischemic stroke. *N Engl J Med*. 1997;337:1309–1310.
- Halsey JH Jr. Prognosis of acute hemiplegia estimated by transcranial Doppler ultrasonography. *Stroke*. 1988;19:648–649.
- Fieschi C, Argentino C, Lenzi GL, Sacchetti ML, Toni D, Bozzao L. Clinical and instrumental evaluation of patients with ischemic stroke within the first six hours. *J Neurol Sci*. 1989;91:311–321.
- Alexandrov AV, Bladin CF, Norris JW. Intracranial blood flow velocities in acute ischemic stroke. *Stroke*. 1994;25:1378–1383.
- Toni D, Fiorelli M, Zanette EM, Sacchetti ML, Salerno A, Argentino C, Solaro M, Fieschi C. Early spontaneous improvement and deterioration of ischemic stroke patients: a serial study with transcranial Doppler ultrasonography. *Stroke*. 1998;29:1144–1148.
- Alexandrov AV, Demchuk AM, Felberg RA, Christou I, Barber P, Burgin WS, Malkoff M, Wojner AW, Grotta JC. High rate of complete recanalization and dramatic clinical recovery during tPA infusion when continuously monitored with 2-MHz transcranial Doppler monitoring. *Stroke*. 2000;31:610–614.
- Burgin WS, Malkoff M, Demchuk AM, Felberg RA, Christou I, Grotta JC, Alexandrov AV. Transcranial Doppler ultrasound criteria for recanalization after thrombolysis for middle cerebral artery stroke. *Stroke*. 2000;31:1128–1132.
- Absher PM, Hendley E, Jaworski DM, Taatjes DJ, Sobel BE. Impairment of the blood-brain barrier: a potential surrogate delineating the determinants of cerebral bleeding caused by fibrinolytic drugs. *Coron Artery Dis*. 1999;10:413–420.
- Busch E, Kruger K, Fritze K, Allegrini PR, Hoehn-Berlage M, Hossmann KA. Blood-brain barrier disturbances after rt-PA treatment of thromboembolic stroke in the rat. *Acta Neurochir Suppl (Wien)*. 1997;70:206–208.
- Asahi M, Asahi K, Wang X, Lo EH. Reduction of tissue plasminogen activator-induced hemorrhage and brain injury by free radical spin trapping after embolic focal cerebral ischemia in rats. *J Cereb Blood Flow Metab*. 2000;20:452–457.