

AHA SCIENTIFIC STATEMENT

Diagnosis and Management of Cerebral Venous Thrombosis: A Scientific Statement From the American Heart Association

Gustavo Saposnik, MD, MPH, PhD, FAHA, Chair; Cheryl Bushnell, MD, MHS, FAHA, Vice Chair; Jonathan M. Coutinho, MD, PhD; Thalia S. Field, MD, MHSc; Karen L. Furie, MD, MPH, FAHA; Najibah Galadanci, MBBS, MPH, PhD; Wayneho Kam, MD; Fenella C. Kirkham, MD; Norma D. McNair, RN, PhD; Aneesh B. Singhal, MD, FAHA; Vincent Thijs, MD, PhD, FAHA; Victor X.D. Yang, MD, PhD; on behalf of the American Heart Association Stroke Council; Council on Cardiopulmonary, Critical Care, Perioperative and Resuscitation; Council on Cardiovascular and Stroke Nursing; and Council on Hypertension

ABSTRACT: Cerebral venous thrombosis accounts for 0.5% to 3% of all strokes. The most vulnerable populations include young individuals, women of reproductive age, and patients with a prothrombotic state. The clinical presentation of cerebral venous thrombosis is diverse (eg, headaches, seizures), requiring a high level of clinical suspicion. Its diagnosis is based primarily on magnetic resonance imaging/magnetic resonance venography or computed tomography/computed tomographic venography. The clinical course of cerebral venous thrombosis may be difficult to predict. Death or dependence occurs in 10% to 15% of patients despite intensive medical treatment. This scientific statement provides an update of the 2011 American Heart Association scientific statement for the diagnosis and management of cerebral venous thrombosis. Our focus is on advances in the diagnosis and management decisions of patients with suspected cerebral venous thrombosis. We discuss evidence for the use of anticoagulation and endovascular therapies and considerations for craniectomy. We also provide an algorithm to optimize the management of patients with cerebral venous thrombosis and those with progressive neurological deterioration or thrombus propagation despite maximal medical therapy.

Key Words: AHA Scientific Statements ■ anticoagulants ■ headaches ■ intracranial thrombosis ■ seizure ■ sinus thrombosis ■ venous thrombosis

Cerebral venous thrombosis (CVT) is the presence of a blood clot in the dural venous sinuses, the cerebral veins, or both.¹ Among those with stroke, CVT represents only 0.5% to 3%.² Registry-based and cohort studies suggest that CVT affects predominantly individuals <55 years of age, with two-thirds occurring in women.² With regard to location, the most commonly affected sinuses are illustrated in Figure 1.¹⁻³

Overall, patients with CVT have a favorable outcome. Most patients with CVT nowadays survive without physical disability, but chronic symptoms, which negatively affect quality of life, are not uncommon. Most common factors associated with poor prognosis include advanced age, active cancer, decreased level of consciousness, and intracerebral hemorrhage, among others.^{1,4,5}

This scientific statement synthesizes the clinical presentation, predisposing factors, advances in imaging modalities and therapies, and management of CVT in special populations (pediatric, pregnancy and puerperium, and vaccine-induced CVT). This document is strengthened by new evidence since our previous publication in 2011.¹ Future areas of research are highlighted.

CLINICAL PRESENTATION

Presenting symptoms of CVT can be due to increased intracranial pressure or focal parenchymal injury, with or without mass effect.¹ Headache is the most common symptom of CVT, occurring in nearly 90% of cases.⁴ Other signs and symptoms related to intracranial

Supplemental Material is available at <https://www.ahajournals.org/doi/suppl/10.1161/STR.0000000000000456>.

© 2024 American Heart Association, Inc.

Stroke is available at www.ahajournals.org/journal/str

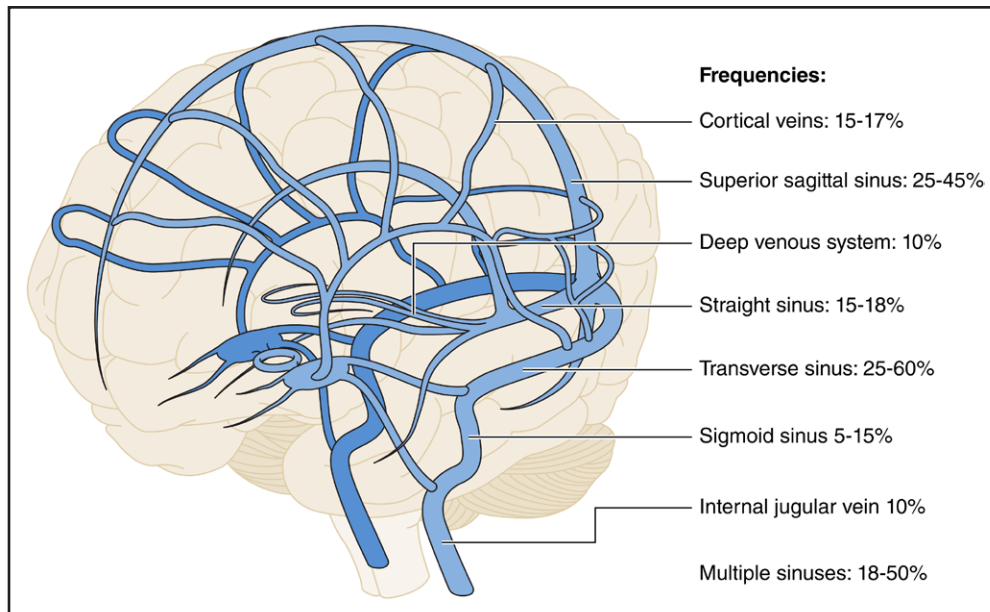


Figure 1. Anatomy of the cerebral venous system and distribution of CVT.

Prevalence of sinus involvement in CVT. Percentages may be >100% because many patients may have >1 sinus involved.¹⁻³ Please note that internal jugular vein thrombosis represents its concomitant prevalence with CVT (not in isolation). CVT indicates cerebral venous thrombosis.

pressure include nausea, transient visual obscurations or vision loss (13%–27%), papilledema, and diplopia (6%–14%).^{2,4,6,7} Other cranial neuropathies can also occur from increased intracranial pressure (6%–11%). Approximately 20% to 40% have seizures at the time of presentation, and 20% to 50% have focal neurological deficits.^{2,4,6-9} Encephalopathy and coma have been reported in up to 20%.^{2,4,6-8} Symptoms tend to occur more insidiously than in other stroke types, and the majority will present >48 hours after onset. A minority may have more acute presentations with thunderclap headache or subarachnoid hemorrhage (<5%) or acute onset of focal neurologic deficits (5%–40%).^{2,4,6-8} Further details are summarized in [Supplemental Table 1](#).

PREDISPOSING FACTORS

Predisposing factors for CVT are identified in the majority of those with the disease and may be transient or chronic (Table).^{10,11} Rates of CVT are highest in younger women, with both oral contraception and pregnancy/ puerperium being major risk factors.^{12,13} Oral contraception and hormonal therapies¹⁴ (primarily those containing estrogen-based formulations) may increase the odds of CVT nearly 8-fold,¹¹ with possible additional synergistic effects with obesity.¹⁵ Other well-established risk factors include acquired thrombophilias such as antiphospholipid antibody syndrome, JAK2 mutations, malignancy, particularly myeloproliferative disorders, and autoimmune disease, including Behçet and inflammatory bowel disease. Genetic thrombophilias such as protein C and protein S deficiency, factor V Leiden, and prothrombin G20210A polymorphism

can be associated with CVT.^{1,4,7,16} Other transient provoking factors commonly reported in previous series include infections (COVID-19, head and neck infections),¹⁷⁻¹⁹ dehydration,^{2,20} other medications such as corticosteroids and L-asparaginase, and vaccine-induced thrombotic thrombocytopenia (VITT).^{1,4} Mechanical provoking factors such as head trauma, neurosurgical procedures, and compressive lesions such as meningiomas impinging on venous sinuses are also associated with CVT.^{1,4,21}

LONG-TERM SYMPTOMS AND CVT RECURRENCE

Overall, 80% to 90% of patients with CVT achieve functional independence (modified Rankin Scale score of 0–2).^{1,4,5} However, several studies reported a high prevalence of residual symptoms related to cognition, mood, fatigue, and headache, which may impede return to previous level of activity.²²⁻²⁴ A prospective cohort from a Canadian randomized trial found that although 72% of individuals with CVT remained functionally independent at the time of their presentation, there was an overall substantial burden of headache, fatigue, low mood, and impaired cognitive performance.²⁵ A retrospective study from China including 303 patients with CVT who were employed or students before their index event found that 42% had not returned to work or school at 6 months, despite 87% reaching functional independence at the time of assessment.²⁶

Epilepsy may affect >10% of individuals with CVT, with risk factors including seizures at the time of onset, decreased level of consciousness or focal deficits,

Table. Predisposing Factors or Medical Conditions Associated With CVT

	Transient	Chronic
Sex-specific and transgender hormonal treatment	Oral contraceptive (54%–71%) Pregnancy/postpartum (11%–59%) Hormone replacement therapy (4%)	Hormone replacement therapy Hormone therapy for transfeminine or transmasculine individuals
Other morbidity	Head and neck infections (8%–11%) Dehydration (2%–19%) Anemia Sepsis Respiratory infections COVID-19 (7.6%)	Obesity (23%) Anemia (9%–27%) Other systemic diseases (thyroid disease, nephrotic syndrome, inflammatory bowel disease; 1%–2%)
Other medications	Corticosteroids L-Asparaginase Thalidomide Tamoxifen	
Malignancy		Myeloproliferative disorders (2%–3%) Other malignancy (7%)
Autoimmune		Antiphospholipid antibody syndrome (6%–17%) Connective tissue disease (systemic lupus erythematosus, Behçet disease, sarcoidosis; 1%)
Other genetic thrombophilia (31%–41%)		Prothrombin 20210A mutation Factor V Leiden mutation MTHFR (C677T) polymorphism Antithrombin deficiency, JAK2, protein C or protein S deficiency (can be genetic or acquired)
Mechanical	Head trauma (1%–3%) Neurosurgical procedures Jugular vein catheterizations (1%–2% iatrogenic)	Compressive lesions of venous sinus (meningioma) Dural arteriovenous fistula

Percentages indicate presence of factors among those with CVT; may be >100% because many patients may have >1 predisposing condition. CVT indicates cerebral venous thrombosis.

hemorrhagic lesions at baseline or superior sagittal sinus involvement, and craniectomy.^{27,28} Dural arteriovenous fistula is a reported complication of CVT, but CVT can also be a sequela of dural arteriovenous fistula. A large retrospective series of 1218 individuals with CVT found a prevalence of new dural arteriovenous fistula of 2.4% at a median follow-up of 8 months (interquartile range, 5–23 months), although no systematic timing or neuroimaging protocol was included in the study.²⁹ A prospective study with systematic imaging collection at 6 months after CVT found no dural arteriovenous fistula.³⁰

The incidence of recurrent venous thromboembolism (VTE) after CVT ranges from 1% to 4% per year, with rates of CVT recurrence generally reported as <1% to 2% per year.^{6,31} A higher risk of recurrence has been reported in individuals with severe thrombophilia (including malignancy), those with a history of VTE, individuals with events without identified precipitants, and, inconsistently, male individuals.^{6,31} A secondary analysis of ACTION-CVT (Anticoagulation in the Treatment of CVT) showed a VTE recurrence of 6.4% (2.5% for CVT recurrent alone although brain images were not centrally

adjudicated).³² A recent retrospective study of VTE recurrence (including CVT) reported rates of 5.68 per 100 patient-years, more than half of which were CVT.⁸ A study from Norway found that individuals with CVT (n=654; median age, 41 years; 67% women) compared with general population age- and sex-matched control subjects were at increased risk of recurrent VTE, ischemic stroke, major bleeding, and mortality at 10 years. Risks of recurrent VTE were higher in younger individuals (age, 18–54 years) with CVT compared with the general population, whereas risks of ischemic stroke, major bleeding, and mortality (risk difference, 11.5% for women ≥55 years of age and 5.8% for men ≥55 years) were highest in older patients.³³

BRAIN AND VASCULAR IMAGING FOR THE DIAGNOSIS OF CVT

Conventional computed tomography (CT) or magnetic resonance imaging (MRI) is often the first test obtained in patients with nonspecific acute presentations and may

show signs that increase suspicion for CVT. For example, CVT on CT or MRI may be suspected by (1) direct visualization of the thrombus, (2) the absence of venous filling, and (3) imaging of the consequences of venous obstruction at the tissue level (venous infarction, edema and hemorrhagic transformation, intracranial hypertension and hydrocephalus) and at the vascular level (dilated veins).^{1,34} Common challenges of brain imaging are summarized in [Supplemental Table 2](#).

Direct imaging of thrombus is possible on CT, especially with the increased use of thin-slice CT (Figure 2A–2D).^{1,35} On noncontrast CT this is observed as hyperattenuation due to increase of hemoglobin and red blood cells within the thrombus (dense vessel sign; Figure 2B–2E). The traditional cord or string sign, a serpiginous or linear hyperdensity within a vein, or dense triangle sign can be present up to 14 days after onset of symptoms (Figure 2E). Indirect signs that raise the suspicion on noncontrast CT (and MRI) include areas of hypodensity not conforming to typical wedge-shaped infarctions or that are not limited to specific arterial territories or sparing the overlying cortex. Bilateral hypodensities may occur when the sagittal sinus or deep cerebral veins are involved. Hemorrhages are present in up to 40% of CVT and include areas of hemorrhagic transformation within regions of hypodensity or frank intracerebral hemorrhage associated with subarachnoid or subdural hemorrhages.^{2,4,16} Isolated subarachnoid

and basal ganglia hemorrhages are uncommon.⁴ The cashew nut sign, a juxtacortical C-shaped hyperdensity, is reported to have a high specificity for CVT but has low sensitivity (Figure 2A).³⁶ Bilateral or multifocal hemorrhages also occur frequently (Figure 2F). In a recent meta-analysis of 27 publications with 2812 cases, CT had a sensitivity of 0.79 (95% CI, 0.76–0.82) and specificity of 0.90 (95% CI, 0.89–0.91),³⁵ lower than previously reported in the 2011 American Heart Association statement.¹

Thrombi can also be directly observed on conventional MRI sequences (Figure 3).^{1,37} Because the evolution of a thrombus on MRI is dynamic, changes in the signal intensity of the thrombus over time are similar to that of a hematoma. As the thrombus ages, oxyhemoglobin is converted to deoxyhemoglobin and methemoglobin, leading to changes in signal characteristics on the T1 and T2 sequences. In these early stages, it is difficult to diagnose thrombosis because T2 may be isointense or hypointense, mimicking a normal flow void of a venous sinus. Similarly, time-of-flight magnetic resonance venography (MRV) is susceptible to misdiagnosis because absent flow is not always corroborated on T1/T2 sequences ([Supplemental Table 2](#)). Consequently, it is often helpful to corroborate findings with gradient-recalled echo, susceptibility-weighted imaging sequences, or contrast-enhanced MRV.^{34,37} Thrombosed blood creates a blooming artifact on gradient-recalled

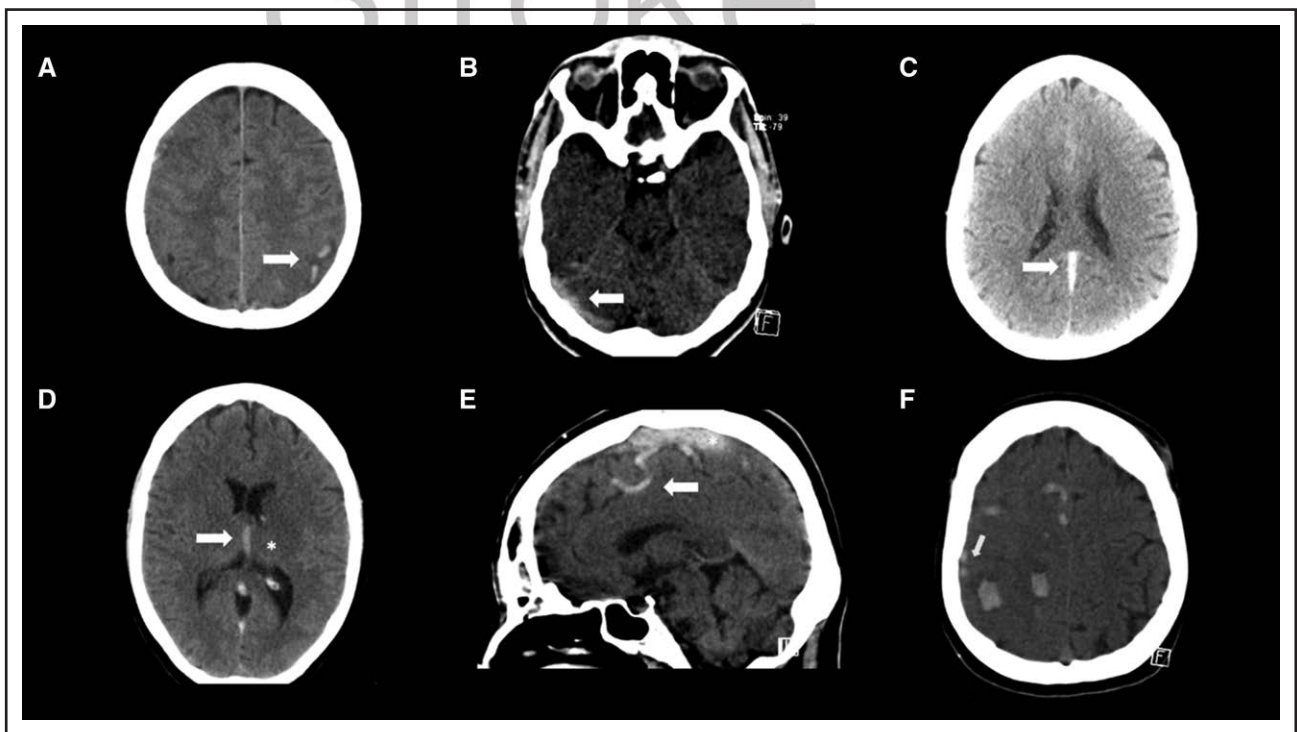


Figure 2. Typical findings of cerebral venous thrombosis on noncontrast computed tomography.

A, Left-sided juxtacortical C-shaped hemorrhages. **B**, Transverse sinus thrombosis. **C**, Straight sinus thrombosis. **D**, Internal cerebral vein thrombosis (arrow) and left thalamic hypodensity (*). **E**, Cord sign (arrow) and hyperdense sagittal sinus thrombosis (*). **F**, Multiple small hemorrhages in same patient as in **E**. Arrows indicate cord sign.

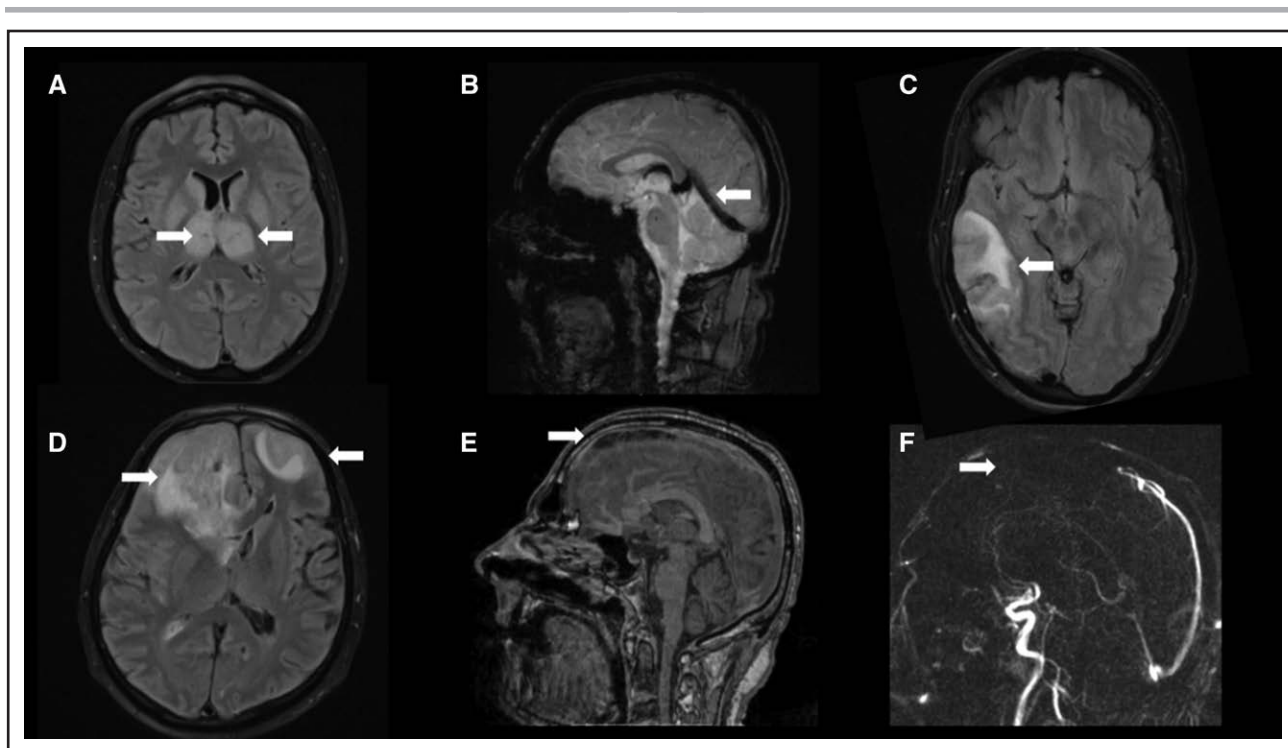


Figure 3. Typical findings of cerebral venous thrombosis on magnetic resonance imaging.

A, Bilateral thalamic hyperintensity (arrows) on fluid-attenuated inversion recovery (FLAIR) in a patient with deep cerebral vein thrombosis. **B**, Susceptibility-weighted imaging shows hypointensity of the straight sinus (arrow), vein of Galen, and internal cerebral veins. **C**, Venous infarction due to transverse sinus thrombosis with heterogeneous FLAIR hyperintensity (arrow). **D**, Bilateral FLAIR hyperintensities (arrows) with mass effect in a patient with superior sagittal sinus thrombosis (arrow), shown in **E** on a contrast-enhanced T1 sequence and in **F** absent venous filling defect (arrow) with phase-contrast magnetic resonance venography.

echo or susceptibility-weighted imaging sequences that is especially useful in the identification of inconspicuous findings (Figure 3B) such as thrombosed cortical veins, where they have a sensitivity and specificity approaching 100%.^{34,37} Advanced MRI techniques such as T1-based black-blood imaging (in which signal from flowing blood is suppressed) are promising. MRI is more sensitive than CT in the detection of parenchymal brain lesions secondary to venous occlusion such as venous infarctions (Figure 3A, 3C, and 3D).³⁸ Radiologically, these lesions cross arterial vascular territories and may be bilateral.

A meta-analysis of 21 studies with 1773 patients with CVT showed conventional MRI sequences to have a sensitivity of 0.82 (95% CI, 0.78–0.85) and specificity of 0.92 (95% CI, 0.91–0.94).³⁵

CONFIRMING THE DIAGNOSIS OF CVT

CT venography and MRV are the optimal tests to confirm a diagnosis of CVT. Digital subtraction angiography is typically used only when invasive treatments are considered.¹

CT venography allows clear depiction of the superficial and deep cerebral venous system. Thrombi present as filling defects (“empty delta sign” referred to the superior sagittal sinus) and can usually be easily distinguished

from arachnoid granulations. Several small to moderately sized studies have demonstrated a high sensitivity and specificity of CTV compared with digital subtraction angiography or a consensus reading of other imaging modalities. Compared with MRI, CTV has a lower sensitivity for cortical vein thrombosis.³⁷

MRV (Figure 3) can be performed without contrast, with time-of-flight (TOF) or phase-contrast techniques, or with a contrast-enhanced technique (Figure 3E and 3F). The use of gadolinium with contrast-enhanced technique allows direct assessment of luminal filling and increases the sensitivity of the detection of thrombus within the smaller veins.^{1,37} Both TOF and phase-contrast MRV techniques can be prone to artifact secondary to complex flow. TOF is, however, still commonly used and is especially useful in situations that may preclude gadolinium administration such as in pregnant or breastfeeding patients or in patients with severe renal failure. Compared with 3-dimensional TOF, 2-dimensional TOF has higher sensitivity in the setting of slow flow. Phase-contrast MRI is used less frequently because defining the velocity of the encoding parameter is not only difficult but operator dependent and requires longer acquisition times. Contrast-enhanced MRV has a sensitivity and specificity comparable to that of CTV but allows better characterization between the low-flow state and hypoplastic

sinus (flow gaps).³⁹ Contrast-enhanced techniques and gradient-recalled echo or susceptibility-weighted imaging are recommended for diagnosing cortical vein thrombosis (new evidence since the 2011 American Heart Association statement).^{1,34,37}

THERAPEUTIC ADVANCES IN THE MANAGEMENT OF CVT

Oral Anticoagulation

The objectives of anticoagulation therapy in CVT are to prevent thrombus growth, to facilitate recanalization, and to prevent recurrent VTE events. Previous American Heart Association/American Stroke Association and European guidelines for the management of CVT recommend the initial use of low-molecular-weight heparin (LMWH) over unfractionated heparin followed by transition to oral vitamin K antagonists (VKAs) for 3 to 12 months in the context of transient risk factors or indefinitely in the context of chronic major risk factors for thrombosis or recurrent VTE (Figure 4).^{1,16,40} LMWH is favored in the acute treatment of CVT given the more practical administration, more predictable anticoagulation effect, lower risk of thrombocytopenia, and trends toward better outcomes in meta-analyses that do not meet the threshold for statistical significance.^{41,42} The presence of venous hemorrhage does not constitute a contraindication for anticoagulation.^{1,16,43} Whether degree of venous recanalization should inform duration of anticoagulation remains an area of uncertainty.^{44–46}

An emerging body of evidence suggests that direct oral anticoagulants (DOACs), which have demonstrated efficacy and safety compared with VKA for individuals with deep venous thrombosis and pulmonary embolism, may also be a reasonable choice for oral anticoagulation in selected individuals with CVT.

RE-SPECT CVT (A Clinical Trial Comparing Efficacy and Safety of Dabigatran Etxilate With Warfarin in Patients With Cerebral Venous and Dural Sinus Thrombosis) was an international prospective clinical trial that randomized 120 individuals with CVT 1:1 to warfarin VKA with target international normalized ratio of 2.0 to 3.0 or dabigatran 150 mg twice daily for 6 months after 5 to 15 days of lead-in parenteral anticoagulation.⁴⁷ The trial excluded individuals with malignancy, central nervous system infection, trauma, and pregnancy. There were no recurrent VTEs in either group, with 1 (1.7% [95% CI, 0.0%–8.9%]) major hemorrhage (gastrointestinal bleeding) in the dabigatran group and 2 (3.3% [95% CI, 0.4%–11.5%]), both intracerebral hemorrhages) in the warfarin group.

SECRET (Study of Rivaroxaban in Cerebral Venous Thrombosis) was a phase II trial that randomized 53 participants with CVT 1:1 to rivaroxaban 20 mg daily versus standard-of-care anticoagulation (warfarin; target international normalized ratio, 2.0–3.0) or LMWH) for a minimum

of 6 months.²⁵ There was no requirement for lead-in parenteral anticoagulation. The trial excluded individuals with pregnancy and antiphospholipid antibody syndrome. Nineteen of 26 individuals in the rivaroxaban group received ≤4 days of lead-in parenteral anticoagulation.

There were no safety concerns related to early initiation of DOAC. By 6 months, there were 1 recurrent CVT (3.8% [95% CI, 0.1%–19.6%]), 1 symptomatic intracerebral hemorrhage (3.8% [95% CI, 0.1%–19.6%]), and 2 clinically relevant nonmajor bleeding events (7.7% [95% CI, 0.9%–25.1%]) in the rivaroxaban group and no VTE recurrence or bleeding events in the control group.

ACTION-CVT, a large retrospective international study, compared events in 845 consecutive individuals with CVT who were prescribed VKA versus DOAC as part of their routine clinical care between 2015 and 2020.⁸ DOACs used included apixaban (67%), rivaroxaban (18%), and dabigatran (14%) or multiple DOACs (3%). Individuals with malignancy, those with antiphospholipid antibody syndrome, and those who were pregnant were excluded. The study found no significant difference in rates of recurrent VTE (adjusted hazard ratio, 0.94 [95% CI, 0.15–1.73]), and there was a reduced risk of major hemorrhage (adjusted hazard ratio, 0.35 [95% CI, 0.15–0.82]), driven primarily by a lower risk of intracerebral hemorrhage, in the DOAC group.⁸ There were no differences in recanalization rates between groups in either study.^{8,47}

A recent systematic review summarizing 3 randomized trials and 16 observational studies comparing DOACs with VKAs found similar rates with both treatments of recurrent VTE, major hemorrhage, and complete recanalization (42.9% versus 42.3%; relative risk, 0.98 [95% CI, 0.87–1.11]).⁴⁸

From the current available evidence, it is reasonable to transition to DOAC or VKA after a period of lead-in parenteral anticoagulation, but whether 5 to 15 days is a safer or more effective strategy than shorter periods is not known.⁴⁷

Additional clinical trials and prospective observational studies are ongoing ([ClinicalTrials.gov](https://clinicaltrials.gov) NCT03178864, NCT04660747). Persistent areas of controversy include timing of initiation with or without lead-in heparin, whether acute VTE dosing is initially required, and optimal candidates for DOAC therapy. DOACs are not suitable in women who are pregnant (both DOAC and warfarin are contraindicated; only LMWH is recommended) or breastfeeding (DOACs are contraindicated; Figure 4). DOACs have also been associated with higher risks of recurrent thromboembolic events compared with warfarin in individuals with antiphospholipid antibody syndrome.^{49,50} For patients with cancer, DOACs were at least noninferior to LMWH in the prevention of VTE. There is limited evidence of the role of antiplatelet agents after discontinuation of oral anticoagulation in CVT. Studies focused on secondary prevention of VTE showed that aspirin was more effective than placebo (hazard ratio, 0.68 [95% CI,

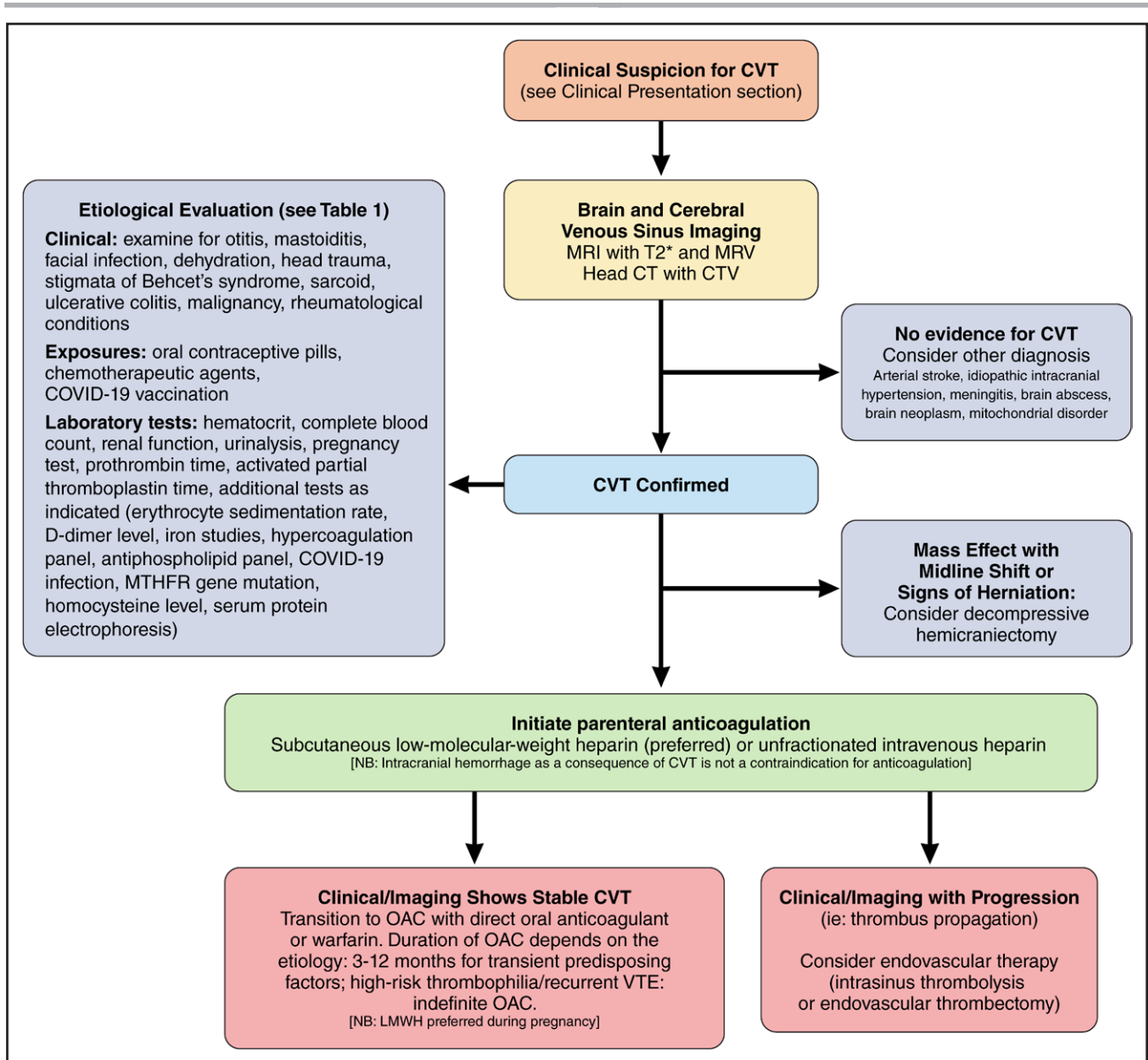


Figure 4. Proposed algorithm for the management of CVT.

This figure summarizes the suggested approach for the diagnosis and management of CVT. CT indicates computed tomography; CTV, computed tomographic venography; CVT, cerebral venous thrombosis; LMWH, low-molecular-weight heparin; MRI, magnetic resonance imaging; MRV, magnetic resonance venography; OAC, oral anticoagulant; and VTE, venous thromboembolism.

0.51–0.90]; $P=0.008$).⁵¹ Compared with all comers with VTE, those with CVT are younger and thus would have a longer lifetime exposure to aspirin. In addition, the CVT literature describing longer-term recurrence risk of VTE is less robust.^{31,33} Thus, potential benefits should be carefully considered along with individual patient characteristics in shared decision-making.

Reperfusion Therapies

Endovascular treatment (EVT) options for the management of CVT could theoretically offer faster recanalization, although any association with a more favorable outcome in medical therapy, particularly in an unselected

population, is uncertain.⁵² Several studies in the past decade that reported the use of mechanical thrombectomy (either balloon assisted or through aspiration or vacuum aspiration systems), intrasinus thrombolysis, combination of mechanical thrombectomy and intrasinus thrombolysis, intra-arterial thrombolysis, and intrasinus stenting provide controversial evidence on safety and complication rates.^{43,53} The multicenter, randomized clinical TO-ACT trial (Thrombolysis or Anticoagulation for CVT) showed that patients with severe CVT did not benefit clinically from EVT compared with the patients receiving standard anticoagulation therapy.⁵⁴ Larger studies and meta-analyses showed that EVT is associated with higher mortality and no evidence of benefit with EVT.^{55–58}

Currently, EVT is used as a rescue treatment for patients who are experiencing clinical deterioration or failed or have contraindications to standard therapy (Figure 4).⁵³ In a systematic review including 10 studies comprising 339 patients who underwent EVT for CVT, the authors found a complete and partial postoperative recanalization in 90.0% of patients, increasing to 95.2% during the follow-up.⁵⁹ The complication rate was 10.3%. There is no current evidence to determine which EVT technique (eg, stent retriever, microcatheters, aspiration catheters, aspiration pump systems) is superior to other therapeutic strategies.

Decompressive Craniectomy

The evidence on decompressive craniectomy for CVT remains unchanged since the previous American Heart Association statement.¹ It should be offered to patients with acute severe CVT and parenchymal lesions with impending herniation as a lifesaving therapeutic approach (Figure 4).⁶⁰ Factors associated with poorer outcomes included age >50 years, midline shift >10 mm, and total effacement of basal cisterns.⁶¹ There are no randomized controlled trials of this surgical approach in the literature. A systematic review and meta-analysis including 51 studies comprising 483 patients with CVT showed that surgery within 48 hours of admission may decrease mortality (odds ratio [OR], 0.26 [95% CI, 0.10–0.69]) and result in improved functional outcomes.⁶²

CVT IN SPECIAL POPULATIONS

Pediatric Population

CVT is more common in neonates (6.4/100 000) than in children and adolescents.⁶³ The key to successful management is to consider the diagnosis early in acute presentations with headache, seizures, focal neurological deficits, or coma and in typical situations such as sepsis (including mastoiditis, Lemierre syndrome, COVID-19, and meningitis), head trauma (including abuse), hypoxia, and dehydration. Awareness is especially important in children with preexisting conditions (congenital heart disease and its surgical treatment, cancer and its treatment, anemia due to iron deficiency or hemoglobinopathies, and inflammatory conditions, eg, nephrotic syndrome and inflammatory bowel disease). Emergency imaging to diagnose or exclude dural or cortical venous thrombosis with or without parenchymal involvement or hemorrhage typically requires anesthesia. Initial blood work may reveal low platelets associated with platelet factor 4 mutations or high platelets and high hemoglobin associated with JAK2 mutations, as well as indices of iron deficiency with or without anemia.^{63,64}

The management of acute CVT in children typically involves LMWH or unfractionated heparin. As for adults, if

there is deterioration in level of consciousness, more invasive procedures should be considered and may potentially be lifesaving (Figure 4). Anticoagulation in the acute phase is more controversial in premature and term neonates but is reasonable because there is no evidence of posttreatment hemorrhage, whereas lack of anticoagulation may lead to thrombus propagation.^{65,66} CVT in children carries a mortality rate of 3%, and recurrent venous thrombosis occurs in ≈6%, usually associated with no administration of anticoagulation and lack of venous recanalization.⁶⁴ Since the prior scientific statement,¹ there have been randomized trials on duration of anticoagulation and the use of DOACs.⁶⁷ In individuals 4 months to 20.9 years of age, the Kids-DOTT trial (Multicenter Evaluation of the Duration of Therapy for Thrombosis in Children) compared 6 weeks with 3 months of anticoagulation for provoked VTE (including 59/417; 25% patients with CVT). Six weeks of anticoagulation was noninferior for recurrent VTE and bleeding events.⁶⁷

In the EINSTEIN-Jr trial (Oral Rivaroxaban in Children With Venous Thrombosis), after initial heparinization, 114 children with confirmed CVT were randomized (2:1) to 3 months of rivaroxaban or standard anticoagulation (continuing heparin or switching to oral VKAs).⁶⁸ The primary efficacy outcome was symptomatic recurrent VTE, and the principal safety outcome was major or clinically relevant nonmajor bleeding. With 100% follow-up, none of the 73 children treated with rivaroxaban compared with 1 of the 41 children treated with standard anticoagulation had symptomatic recurrent VTE (absolute difference, 2.4% [95% CI, –2.6% to 13.5%]). Five patients on rivaroxaban had nonmajor and noncerebral bleeding, whereas 1 patient on standard anticoagulation had a major subdural bleed. Complete or partial recanalization occurred in 18 (25%) and 39 (53%) patients on rivaroxaban and 6 (15%) and 24 (59%) patients on standard anticoagulation. No children died by the end of the 3-month study treatment period. Focal neurological deficits were observed in 5 (6.8%) and 3 (7.3%) children in the rivaroxaban and standard anticoagulation group, respectively, at the end of the study. However, other long-term studies suggest that despite treatment 1 in 4 children may develop late epilepsy,⁶⁹ infantile spasms after neonatal CVT, cognitive impairment, or intracranial hypertension.⁷⁰

CVT During Pregnancy and Puerperium

Pregnancy induces changes in the coagulation system that persist into the puerperium and result in a hypercoagulable state, increasing the risk of CVT. Incidence estimates during pregnancy and the puerperium range from 1 in 2500 deliveries to 1 in 10 000 deliveries in Western countries, and ORs range from 1.3 to 13.0. The greatest risk periods for CVT include the third trimester and the first 6 postpartum weeks. Approximately 80% of pregnancy-related CVT cases occur after delivery.¹² A

case-control study found that the risk is increased only in the puerperium (OR, 10.6 [95% CI, 5.6–20.0]), whereas there was no statistically significant increased risk of CVT during pregnancy (OR, 1.2 [95% CI, 0.6–2.3]).¹⁰ Cesarean delivery appears to be associated with a higher risk after adjustment for age, vascular risk factors, presence of infections, hospital type, and location (OR, 3.10 [95% CI, 2.26–4.24]).¹⁰ Overall, studies published since the prior scientific statement¹ have found that the prognosis for women with pregnancy-related CVT is better than or the same as that for patients with CVT in general.⁷¹

VKAs, including warfarin, are associated with fetal embryopathy and bleeding in the fetus and neonate and thus are contraindicated in pregnancy. Therefore, anticoagulation for CVT during pregnancy and early in the puerperium consists of LMWH in the majority of women.^{12,72,73} There is limited evidence on endovascular therapies in this population. As in nonpregnant women, thrombolysis and thrombectomy are reserved for patients with neurological deterioration or propagation of the thrombus despite medical therapy (Figure 4).

Future Pregnancies and Recurrence

Women with a history of VTE appear to have an increased risk of thrombotic events (ie, deep venous thrombosis, pulmonary embolism) in future pregnancies.⁶⁴ A systematic review comprising 17 studies and 393 pregnancies found a recurrence rate of 8 per 1000 pregnancies (95% CI, 3–22). The rate of noncerebral VTEs was 22 per 1000 pregnancies (95% CI, 11–43).⁷⁴ There was a trend toward a lower rate of recurrent thrombotic events in women who used antithrombotic prophylaxis.⁷⁴

According to the available evidence, CVT is not a contraindication for future pregnancies.^{12,72,75} Considering the additional risk that pregnancy confers to women with a history of CVT, prophylaxis with LMWH during future pregnancies and the postpartum period is probably beneficial.⁷⁵

VITT and CVT

In 2021, reports from Europe and the United States described thrombocytopenia and CVT after vaccination with the ChAdOx1 nCoV-19 vaccine (AstraZeneca) and the Ad26.COV2.S adenovirus-based SARS-CoV-2 vaccine (Janssen).^{76–78} The age range of affected patients was 18 to 77 years; most were women. Symptoms began 5 to 24 days after vaccination.⁷⁶ Headache was the most common presenting feature. All patients had thrombocytopenia. In the United Kingdom, 23 patients with antibodies to platelet factor 4 after ChAdOx1 nCoV-19 vaccination were described. It is believed that DNA from the adenovirus-infected cells bonded to platelet factor 4 and triggered the production of autoantibodies.^{79,80} Although CVT in VITT is a rare condition,⁸¹ it carries a

poor prognosis, with mortality rates ranging from 39% to 61% in initial cohort studies.^{80,82,83} A study on the global impact of COVID-19 that included 2313 CVT admissions across 1 prepandemic year (2019) and 1 pandemic year (2020) found 26 cases of VITT, resulting in 6 deaths. A diagnosis of COVID-19 infection was present in 7.6% of all CVT admissions.¹⁹

A pharmacovigilance study comprising >1.7 million adverse reactions showed a disproportionately lower incident risk of CVT after vaccination with mRNA SARS-CoV-2 vaccines compared with adenovirus-based SARS-CoV-2 vaccines (1–5/10 000 for BNT162b2 and mRNA-1273 versus 13/10 000 for ChAdOx1 nCoV-19 vaccine).⁸⁴ In addition, there is no evidence of VITT after mRNA vaccines.^{76,84}

In cases of suspected VITT, laboratory testing for platelet factor 4 antibodies is recommended. Despite the lack of evidence, given the similarity to autoimmune heparin-induced thrombocytopenia, avoidance of heparin products, intravenous immunoglobulin 1 g/kg body weight daily for 2 days, and administration of steroids have been advised. Platelet transfusions are not recommended.⁸⁵ Nonheparin parenteral anticoagulants (argatroban, fondaparinux) are typically used first, with transition to an oral anticoagulant (ie, DOAC) once there is full platelet count recovery.⁸⁰

KEY POINTS FOR CLINICAL PRACTICE

- CVT requires a high level of suspicion among patients presenting with common symptoms and known predisposing conditions (pregnancy, puerperium, use of oral contraceptives, thrombophilia) or demographic factors (young women).
- New predisposing conditions (obesity, COVID-19, vaccine-induced thrombocytopenia)^{2,15,18} were identified since our previous report.¹ (New)
- MRI/MRV is the recommended noninvasive study of the cerebral venous system to confirm the diagnosis. CT/CTV is a reasonable alternative in centers with limited resources or if the pretest probability is low.
- Contrast-enhanced MRV, gradient-recalled echo, or susceptibility-weighted imaging sequences are the recommended techniques for the diagnosis of cortical venous thrombosis. (New)
- The mainstream initial treatment of CVT includes parenteral heparin followed by transition to oral VKAs for 3 to 12 months, depending on the underlying cause, or indefinitely in the presence of thrombophilia or recurrent VTE (Figure 4).
- DOACs appear to be a safe and effective alternative option to VKAs according to open-label retrospective and prospective randomized studies. (New)
- The strategy of identifying venous recanalization in subsequent CTV or MRV to guide the duration of anticoagulation remains uncertain. (New)
- Given the lack of controlled studies (and poorer outcomes in meta-analyses), endovascular therapies

are reserved for patients with evidence of thrombus propagation, for individuals with neurological deterioration despite medical therapy, or for those with contraindications to anticoagulation (Figure 4). (New)

- Despite the low level of evidence, decompressive surgery is a lifesaving procedure that may result in improved functional outcomes among patients with advanced clinical signs of herniation. (New)
- For women with CVT during pregnancy, LMWH in full anticoagulant doses should be continued throughout pregnancy, and LMWH or VKA with a target international normalized ratio of 2.0 to 3.0 should be continued for at least 6 weeks postpartum (for a total minimum duration of therapy of 3 months).
- It is reasonable to advise women with a history of CVT that future pregnancy is not contraindicated. Prophylaxis with LMWH during future pregnancies and the postpartum period is usually recommended.
- CVT in the pediatric population is more common in neonates than children, usually among those exposed to infections, dehydration, iron deficiency, anemia, or head trauma. Parenteral anticoagulation is also the first-line treatment, followed by LMWH, VKA, or rivaroxaban for at least 6 weeks.
- VITT and CVT may occur (rarely) days or a few weeks after an individual receives adenovirus-based SARS-CoV-2 vaccines, usually presenting with new onset of headaches and thrombocytopenia; it requires the expert management of a hematologist and multidisciplinary team. (New)

ARTICLE INFORMATION

The American Heart Association makes every effort to avoid any actual or potential conflicts of interest that may arise as a result of an outside relationship or a personal, professional, or business interest of a member of the writing panel. Specifically, all members of the writing group are required to complete and submit a Disclosure Questionnaire showing all such relationships that might be perceived as real or potential conflicts of interest.

This statement was approved by the American Heart Association Science Advisory and Coordinating Committee on October 11, 2023, and the American Heart Association Executive Committee on December 4, 2023. A copy of the document is available at <https://professional.heart.org/statements> by using either "Search for Guidelines & Statements" or the "Browse by Topic" area. To purchase additional reprints, call 215-356-2721 or email Meredith.Edelman@wolterskluwer.com

The American Heart Association requests that this document be cited as follows: Saposnik G, Bushnell C, Coutinho JM, Field TS, Furie KL, Galadanci N, Kam W, Kirkham FC, McNair ND, Singhal AB, Thijs V, Yang VXD; on behalf of the American Heart Association Stroke Council; Council on Cardiopulmonary, Critical Care, Perioperative and Resuscitation; Council on Cardiovascular and Stroke Nursing; and Council on Hypertension. Diagnosis and management of cerebral venous thrombosis: a scientific statement from the American Heart Association. *Stroke*. 2024;55:e000000000000456. doi: 10.1161/STR.0000000000000456

The expert peer review of AHA-commissioned documents (eg, scientific statements, clinical practice guidelines, systematic reviews) is conducted by the AHA Office of Science Operations. For more on AHA statements and guidelines development, visit <https://professional.heart.org/statements>. Select the "Guidelines & Statements" drop-down menu, then click "Publication Development."

Permissions: Multiple copies, modification, alteration, enhancement, and distribution of this document are not permitted without the express permission of the American Heart Association. Instructions for obtaining permission are located at <https://www.heart.org/permissions>. A link to the "Copyright Permissions Request Form" appears in the second paragraph (<https://www.heart.org/en/about-us/statements-and-policies/copyright-request-form>).

Acknowledgments

The authors appreciate the support of Dr Gokce H. Majernik (vascular fellow at the London Health Sciences Center, London, Ontario, Canada) for reviewing the section on endovascular therapy in CVT.

Disclosures

Writing Group Disclosures

Writing group member	Employment	Research grant	Other research support	Speakers' bureau/honoraria	Expert witness	Ownership interest	Consultant/advisory board	Other
Gustavo Saposnik	St Michael's Hospital, University of Toronto (Canada)	None	None	None	None	None	None	None
Cheryl Bushnell	Wake Forest School of Medicine	None	None	None	None	None	None	None
Jonathan M. Coutinho	Amsterdam UMC, University of Amsterdam (Netherlands)	Bayer*; AstraZeneca*; Dutch Heart Foundation (nonprofit organization)*; Dutch Thrombosis Foundation (nonprofit organization)*; ZonMw (nonprofit government organization)*; All fees paid to his employer for all.	None	None	None	TrianeCT*	None	None
Thalia S. Field	University of British Columbia Centre for Brain Health (Canada)	Canadian Institutes of Health Research (research grant to her institution)†; Heart and Stroke Foundation of Canada (research grant to her institution)†; Bayer Canada (in-kind study medication)†	None	None	Canadian Medical Protective Association*	DESTINE Health*	None	None
Karen L Furie	Rhode Island Hospital	None	None	None	None	None	None	None

(Continued)

Stroke

Writing Group Disclosures Continued

Writing group member	Employment	Research grant	Other research support	Speakers' bureau/honoraria	Expert witness	Ownership interest	Consultant/advisory board	Other
Najibah Galadanci	University of Alabama at Birmingham	None	None	None	None	None	None	None
Wayneho Kam	Duke University Hospital; UNC Health Rex Comprehensive Stroke Center	None	None	None	None	None	None	None
Fenella J. Kirkham	UCL GOSH Institute of Child Health (United Kingdom)	Action Medical Research (RCT of Montelukast in SCD with processing speed end point)†	None	None	None	None	Pfizer†	UCL (professor of pediatric neurology)†
Norma D. McNair	Retired Nursing	None	None	None	None	None	None	None
Aneesh B. Singhal	Massachusetts General Hospital	MGH Fireman Vascular Center (SPARK Award)*	None	None	MedicoLegal expert witness*	None	None	None
Vincent Thijs	Florey Neurology (Australia)	None	None	Boehringer Ingelheim*	None	None	None	None
Victor X. D. Yang	Sunnybrook Health Sciences Center (Canada)	None	None	None	None	None	None	None

This table represents the relationships of writing group members that may be perceived as actual or reasonably perceived conflicts of interest as reported on the Disclosure Questionnaire, which all members of the writing group are required to complete and submit. A relationship is considered to be "significant" if (a) the person receives \$5000 or more during any 12-month period, or 5% or more of the person's gross income; or (b) the person owns 5% or more of the voting stock or share of the entity, or owns \$5000 or more of the fair market value of the entity. A relationship is considered to be "modest" if it is less than "significant" under the preceding definition.

*Modest.

†Significant.



Reviewer Disclosures

Reviewer	Employment	Research grant	Other research support	Speakers' bureau/honoraria	Expert witness	Ownership interest	Consultant/advisory board	Other
Ekaterina Bakradze	University of Alabama at Birmingham	None	None	None	None	None	None	None
José Ferro	Faculdade de Medicina, Universidade de Lisboa (Portugal)	None	None	None	None	None	None	None
Matthew Frosch	Massachusetts General Hospital	None	None	None	None	None	None	None
Hans-Christian Koennecke	Vivantes Klinikum im Friedrichshain (Germany)	None	None	None	None	None	None	Medical guidelines (I am member of the writing group for guidelines for cerebral venous thrombosis of the Deutsche Gesellschaft für Neurologie [German Neurological Society])*
Thanh Nguyen	Boston University Chobanian and Avedisian School of Medicine	None	None	None	None	None	Idorsia*	None
Brian Silver	UMass Memorial Medical Center	None	None	None	None	None	None	None
Kori Zachrison	Massachusetts General Hospital	None	None	None	None	None	None	None

This table represents the relationships of reviewers that may be perceived as actual or reasonably perceived conflicts of interest as reported on the Disclosure Questionnaire, which all reviewers are required to complete and submit. A relationship is considered to be "significant" if (a) the person receives \$5000 or more during any 12-month period, or 5% or more of the person's gross income; or (b) the person owns 5% or more of the voting stock or share of the entity, or owns \$5000 or more of the fair market value of the entity. A relationship is considered to be "modest" if it is less than "significant" under the preceding definition.

*Modest.

Downloaded from <http://ahajournals.org> by on January 31, 2024

REFERENCES

- Saposnik G, Barinagarrementeria F, Brown RD Jr, Bushnell CD, Cucchiara B, Cushman M, deVeber G, Ferro JM, Tsai FY; on behalf of the American Heart Association Stroke Council and the Council on Epidemiology and Prevention. Diagnosis and management of cerebral venous thrombosis: a statement for healthcare professionals from the American Heart Association/American Stroke Association. *Stroke*. 2011;42:1158–1192. doi: 10.1161/STR.0b013e31820a8364
- Alet M, Ciardi C, Alemán A, Bando L, Bonardo P, Cea C, Cirio J, Cossio J, Cuculic M, Esnaola MM, et al. Cerebral venous thrombosis in Argentina: clinical presentation, predisposing factors, outcomes and literature review. *J Stroke Cerebrovasc Dis*. 2020;29:105145. doi: 10.1016/j.jstrokecerebrovasdis.2020.105145
- Maali L, Khan S, Qeadan F, Ismail M, Ramaswamy D, Hedna VS. Cerebral venous thrombosis: continental disparities. *Neurol Sci*. 2017;38:1963–1968. doi: 10.1007/s10072-017-3082-7
- Ferro JM, Canhao P, Stam J, Bousser MG, Barinagarrementeria F; ISCVT Investigators. Prognosis of cerebral vein and dural sinus thrombosis: results of the International Study on Cerebral Vein and Dural Sinus Thrombosis (ISCVT). *Stroke*. 2004;35:664–670. doi: 10.1161/01.STR.0000117571.76197.26
- Klein P, Shu L, Nguyen TN, Siegler JE, Omran SS, Simpkins AN, Heldner M, Havenon A, Aparicio HJ, Abdalkader M, et al. Outcome prediction in cerebral venous thrombosis: the IN-REvASC Score. *J Stroke*. 2022;24:404–416. doi: 10.5853/jos.2022.01606
- Martinelli I, Bucciarelli P, Passamonti SM, Battaglioli T, Previtali E, Mannucci PM. Long-term evaluation of the risk of recurrence after cerebral sinus-venous thrombosis. *Circulation*. 2010;121:2740–2746. doi: 10.1161/CIRCULATIONAHA.109.927046
- Duman T, Uluduz D, Midi I, Bektas H, Kablan Y, Goksel BK, Milanlioglu A, Necioglu Orken D, Aluclu U. A multicenter study of 1144 patients with cerebral venous thrombosis: the VENOST study. *J Stroke Cerebrovasc Dis*. 2017;26:1848–1857. doi: 10.1016/j.jstrokecerebrovasdis.2017.04.020
- Yaghi S, Shu L, Bakradze E, Salehi Omran S, Giles JA, Amar JY, Henninger N, Elnazeir M, Liberman AL, Moncrieffe K, et al. Direct oral anticoagulants versus warfarin in the treatment of cerebral venous thrombosis (ACTION-CVT): a multicenter international study. *Stroke*. 2022;53:728–738. doi: 10.1161/STROKEAHA.121.037541
- Lindgren E, Silvis SM, Hiltunen S, Heldner MR, Serrano F, de Scisco M, Zelano J, Zuurbier SM, Sanchez van Kammen M, Mansour M, et al. Acute symptomatic seizures in cerebral venous thrombosis. *Neurology*. 2020;95:e1706–e1715. doi: 10.1212/WNL.00000000000010577
- Silvis SM, Lindgren E, Hiltunen S, Devasagayam S, Scheres LJ, Jood K, Zuurbier SM, Kleinig TJ, Silver FL, Mandell DM, et al. Postpartum period is a risk factor for cerebral venous thrombosis. *Stroke*. 2019;50:501–503. doi: 10.1161/STROKEAHA.118.023017
- Amoozegar F, Ronskley PE, Sauve R, Menon BK. Hormonal contraceptives and cerebral venous thrombosis risk: a systematic review and meta-analysis. *Front Neurol*. 2015;6:7. doi: 10.3389/fneur.2015.00007
- Khan M, Arauz A, Uluduz D, Barboza MA, Duman T, Cano-Nigenda V, Awan S, Wasay M; VENOST Study Group. Predictors of mortality and functional outcome in pregnancy and puerperium-related cerebral venous thrombosis. *Cerebrovasc Dis*. 2023;52:393–400. doi: 10.1159/000527155
- Kashkoush AI, Ma H, Agarwal N, Panczykowski D, Tonetti D, Weiner GM, Ares W, Kenmair C, Jadhav A, Jovin T, et al. Cerebral venous sinus thrombosis in pregnancy and puerperium: a pooled, systematic review. *J Clin Neurosci*. 2017;39:9–15. doi: 10.1016/j.jocn.2017.02.046
- Getahun D, Nash R, Flanders WD, Baird TC, Becerra-Culqui TA, Cromwell L, Hunkeler E, Lash TL, Millman A, Quinn VP, et al. Cross-sex hormones and acute cardiovascular events in transgender persons: a cohort study. *Ann Intern Med*. 2018;169:205–213. doi: 10.7326/m17-2785
- Zuurbier SM, Arnold M, Middeldorp S, Broeg-Morvay A, Silvis SM, Heldner MR, Meisterernst J, Nemeth B, Meulendijks ER, Stam J, et al. Risk of cerebral venous thrombosis in obese women. *JAMA Neurol*. 2016;73:579–584. doi: 10.1001/jamaneurol.2016.0001
- Ferro JM, Bousser MG, Canhão P, Coutinho JM, Crassard I, Dentali F, di Minno M, Maino A, Martinelli I, Masuhr F, et al. European Stroke Organization guideline for the diagnosis and treatment of cerebral venous thrombosis. *Eur J Neurol*. 2017;24:1203–1213. doi: 10.1111/ene.13381
- King A, Doyle KM. Implications of COVID-19 to stroke medicine: an epidemiological and pathophysiological perspective. *Curr Vasc Pharmacol*. 2022;20:333–340. doi: 10.2174/1570161120666220428101337
- Simonetto M, Wechsler PM, Merkler AE. Stroke treatment in the era of COVID-19: a review. *Curr Treat Options Neurol*. 2022;24:155–171. doi: 10.1007/s11940-022-00713-8
- Nguyen TN, Qureshi MM, Klein P, Yamagami H, Abdalkader M, Mikulik R, Sathya A, Mansour OY, Czlonkowska A, Lo H, et al. Global impact of the COVID-19 pandemic on cerebral venous thrombosis and mortality. *J Stroke*. 2022;24:256–265. doi: 10.5853/jos.2022.00752
- Liu K, Pei L, Gao Y, Zhao L, Fang H, Bunda B, Fisher L, Wang Y, Li S, Li Y, et al. Dehydration status predicts short-term and long-term outcomes in patients with cerebral venous thrombosis. *Neurocrit Care*. 2019;30:478–483. doi: 10.1007/s12028-018-0628-3
- Shabo E, Wach J, Hamed M, Guresir A, Weinhold L, Vatter H, Guresir E. Asymptomatic postoperative cerebral venous sinus thrombosis after posterior fossa tumor surgery: incidence, risk factors, and therapeutic options. *Neurosurgery*. 2023;92:1171–1176. doi: 10.1227/neu.0000000000002340
- Hiltunen S, Putaala J, Haapaniemi E, Tatlisumak T. Long-term outcome after cerebral venous thrombosis: analysis of functional and vocational outcome, residual symptoms, and adverse events in 161 patients. *J Neurol*. 2016;263:477–484. doi: 10.1007/s00415-015-7996-9
- Koopman K, Uyttenboogaart M, Vroomen PC, van der Meer J, De Keyser J, Luijckx GJ. Long-term sequelae after cerebral venous thrombosis in functionally independent patients. *J Stroke Cerebrovasc Dis*. 2009;18:198–202. doi: 10.1016/j.jstrokecerebrovasdis.2008.10.004
- Preter M, Tzourio C, Ameri A, Bousser MG. Long-term prognosis in cerebral venous thrombosis: follow-up of 77 patients. *Stroke*. 1996;27:243–246. doi: 10.1161/01.str.27.2.243
- Field T, Dizonno V, Almekhlafi MA, Bala F, Alhabli I, Wong H, Norena M, Villaluna MK, King-Azote P, Ratnaweera N, et al; SECRET Investigators. Study of Rivaroxaban in Cerebral Venous Thrombosis: a randomized controlled feasibility trial comparing anticoagulation with rivaroxaban to standard-of-care in symptomatic cerebral venous thrombosis. *Stroke*. 2023;54:2724–2736. doi: 10.1161/STROKEAHA.123.044113
- Liu L, Jiang H, Wei H, Zhou Y, Wu Y, Zhang K, Duan J, Meng R, Zhou C, Ji X. Risk factors of impaired employability after cerebral venous thrombosis. *CNS Neurosci Ther*. 2023;29:1086–1093. doi: 10.1111/cns.14083
- Gasparini S, Neri S, Brigo F, Cianci V, Mammì A, Pascarella A, Manzo L, Benna P, Striano P, Martino T, et al. Late epileptic seizures following cerebral venous thrombosis: a systematic review and meta-analysis. *Neurol Sci*. 2022;43:5229–5236. doi: 10.1007/s10072-022-06148-y
- Sanchez van Kammen M, Lindgren E, Silvis SM, Hiltunen S, Heldner MR, Serrano F, Zelano J, Zuurbier SM, Mansour M, Aguiar de Sousa D, et al. Late seizures in cerebral venous thrombosis. *Neurology*. 2020;95:e1716–e1723. doi: 10.1212/WNL.00000000000010576
- Lindgren E, Rentzos A, Hiltunen S, Serrano F, Heldner MR, Zuurbier SM, Silvis SM, Mansour M, Allingham W, Punter MNM, et al. Dural arteriovenous fistulas in cerebral venous thrombosis: data from the International Cerebral Venous Thrombosis Consortium. *Eur J Neurol*. 2022;29:761–770. doi: 10.1111/ene.15192
- Ferro JM, Coutinho JM, Jansen O, Bendszus M, Dentali F, Kobayashi A, van der Veen B, Miede C, Caria J, Huisman H, et al. Dural arteriovenous fistulae after cerebral venous thrombosis. *Stroke*. 2020;51:3344–3347. doi: 10.1161/STROKEAHA.120.031235
- Palazzo P, Agius P, Ingrand P, Ciron J, Lamy M, Berthomet A, Cantagrel P, Neau JP. Venous thrombotic recurrence after cerebral venous thrombosis: a long-term follow-up study. *Stroke*. 2017;48:321–326. doi: 10.1161/strokeaha.116.015294
- Shu L, Bakradze E, Omran SS, Giles J, Amar J, Henninger N, Elnazeir M, Liberman A, Moncrieffe K, Rotblat J, et al. Predictors of recurrent venous thrombosis after cerebral venous thrombosis: analysis of the ACTION-CVT study. *Neurology*. 2022;99:e2368–e2377. doi: 10.1212/wnl.000000000000201122
- Skajaa N, Vandenbroucke JP, Simonsen CZ, Sørensen HT, Adelborg K. Thromboembolic events, bleeding, and mortality in patients with cerebral venous thrombosis: a nationwide cohort study. *Blood Adv*. 2023;7:2070–2081. doi: 10.1182/bloodadvances.2022008622
- Dmytriw AA, Song JSA, Yu E, Poon CS. Cerebral venous thrombosis: state of the art diagnosis and management. *Neuroradiology*. 2018;60:669–685. doi: 10.1007/s00234-018-2032-2
- Xu W, Gao L, Li T, Ramdoyal ND, Zhang J, Shao A. The performance of CT versus MRI in the differential diagnosis of cerebral venous thrombosis. *Thromb Haemost*. 2018;118:1067–1077. doi: 10.1055/s-0038-1642636
- Coutinho JM, van den Berg R, Zuurbier SM, VanBavel E, Troost D, Majoie CB, Stam J. Small juxtacortical hemorrhages in cerebral venous thrombosis. *Ann Neurol*. 2014;75:908–916. doi: 10.1002/ana.24180
- van Dam LF, van Walderveen MAA, Kroft LJM, Kruijff ND, Wermer MJH, van Osch MJP, Huisman MV, Klok FA. Current imaging modalities for

- diagnosing cerebral vein thrombosis: a critical review. *Thromb Res*. 2020;189:132–139. doi: 10.1016/j.thromres.2020.03.011
38. Alajmi E, Zung J, Duquet-Armand M, Coutinho JM, Mandell DM. Prevalence of venous infarction in patients with cerebral venous thrombosis: baseline diffusion-weighted MRI and follow-up MRI. *Stroke*. 2023;54:1808–1814. doi: 10.1161/STROKEAHA.122.042336
 39. Pai V, Khan I, Sitho YY, Purohit B. Pearls and pitfalls in the magnetic resonance diagnosis of dural sinus thrombosis: a comprehensive guide for the trainee radiologist. *J Clin Imaging Sci*. 2020;10:77. doi: 10.25259/jcis_187_2020
 40. Einhüupl K, Stam J, Bousser MG, De Bruijn SF, Ferro JM, Martinelli I, Masuhr F; European Federation of Neurological Societies. EFNS guideline on the treatment of cerebral venous and sinus thrombosis in adult patients. *Eur J Neurol*. 2010;17:1229–1235. doi: 10.1111/j.1468-1331.2010.03011.x
 41. Misra UK, Kalita J, Chandra S, Kumar B, Bansal V. Low molecular weight heparin versus unfractionated heparin in cerebral venous sinus thrombosis: a randomized controlled trial. *Eur J Neurol*. 2012;19:1030–1036. doi: 10.1111/j.1468-1331.2012.03690.x
 42. Erkens PM, Prins MH. Fixed dose subcutaneous low molecular weight heparins versus adjusted dose unfractionated heparin for venous thromboembolism. *Cochrane Database Syst Rev*. 2010:CD001100. doi: 10.1002/14651858.CD001100.pub3
 43. Fan Y, Yu J, Chen H, Zhang J, Duan J, Mo D, Zhu W, Wang B, Ouyang F, Chen Y, et al. Chinese Stroke Association guidelines for clinical management of cerebrovascular disorders: executive summary and 2019 update of clinical management of cerebral venous sinus thrombosis. *Stroke Vasc Neurol*. 2020;5:152–158. doi: 10.1136/svn-2020-000358
 44. Aguiar de Sousa D, Lucas Neto L, Arauz A, Sousa AL, Gabriel D, Correia M, Gil-Gouveia R, Penas S, Carvalho Dias M, Correia MA, et al. Early recanalization in patients with cerebral venous thrombosis treated with anticoagulation. *Stroke*. 2020;51:1174–1181. doi: 10.1161/STROKEAHA.119.028532
 45. Ferro JM, Bendszus M, Jansen O, Coutinho JM, Dentali F, Kobayashi A, Aguiar de Sousa D, Neto LL, Miede C, Caria J, et al. Recanalization after cerebral venous thrombosis: a randomized controlled trial of the safety and efficacy of dabigatran etexilate versus dose-adjusted warfarin in patients with cerebral venous and dural sinus thrombosis. *Int J Stroke*. 2022;17:189–197. doi: 10.1177/17474930211006303
 46. Kim DJ, Honig A, Alimohammadi A, Sepelny AA, Zhou LW, Field TS. Recanalization and outcomes after cerebral venous thrombosis: a systematic review and meta-analysis. *Res Pract Thromb Haemost*. 2023;7:100143. doi: 10.1016/j.rpth.2023.100143
 47. Ferro JM, Coutinho JM, Dentali F, Kobayashi A, Alasheev A, Canhão P, Karpov D, Nagel S, Posthuma L, Loriz JM, et al. Safety and efficacy of dabigatran etexilate vs dose-adjusted warfarin in patients with cerebral venous thrombosis: a randomized clinical trial. *JAMA Neurol*. 2019;76:1457–1465. doi: 10.1001/jamaneurol.2019.2764
 48. Yaghi S, Saldanha IJ, Misquith C, Zaidat B, Shah A, Joudi K, Persaud B, Abdul Khalek F, Shu L, de Havenon A, et al. Direct oral anticoagulants versus vitamin K antagonists in cerebral venous thrombosis: a systematic review and meta-analysis. *Stroke*. 2022;53:3014–3024. doi: 10.1161/STROKEAHA.122.039579
 49. Ordi-Ros J, Sáez-Comet L, Pérez-Conesa M, Vidal X, Riera-Mestre A, Castro-Salomó A, Cuquet-Pedragosa J, Ortiz-Santamaria V, Mauri-Plana M, Solé C, et al. Rivaroxaban versus vitamin K antagonist in antiphospholipid syndrome: a randomized noninferiority trial. *Ann Intern Med*. 2019;171:685–694. doi: 10.7326/M19-0291
 50. Woller SC, Stevens SM, Kaplan D, Wang T-F, Branch DW, Groat D, Wilson EL, Armbruster B, Aston VT, Lloyd JF, et al. Apixaban compared with warfarin to prevent thrombosis in thrombotic antiphospholipid syndrome: a randomized trial. *Blood Adv*. 2022;6:1661–1670. doi: 10.1182/bloodadvances.2021005808
 51. Simes J, Becattini C, Agnelli G, Eikelboom JW, Kirby AC, Mister R, Prandoni P, Brighton TA. Aspirin for the prevention of recurrent venous thromboembolism. *Circulation*. 2014;130:1062–1071. doi: 10.1161/CIRCULATIONAHA.114.008828
 52. Coutinho JM, Middeldorp S, Stam J. Advances in the treatment of cerebral venous thrombosis. *Curr Treat Options Neurol*. 2014;16:299. doi: 10.1007/s11940-014-0299-0
 53. Lewis W, Saber H, Sadeghi M, Rajah G, Narayanan S. Transvenous endovascular recanalization for cerebral venous thrombosis: a systematic review and meta-analysis. *World Neurosurg*. 2019;130:341–350. doi: 10.1016/j.wneu.2019.06.211
 54. Coutinho JM, Zuurbier SM, Bousser MG, Ji X, Canhao P, Roos YB, Crassard I, Nunes AP, Uyttenboogaart M, Chen J, et al. Effect of endovascular treatment with medical management vs standard care on severe cerebral venous thrombosis: the TO-ACT randomized clinical trial. *JAMA Neurol*. 2020;77:966–973. doi: 10.1001/jamaneurol.2020.1022
 55. Siddiqui FM, Weber MW, Dandapat S, Scaife S, Buhnerkempe M, Ortega-Gutierrez S, Aksan N, Elias A, Coutinho JM. Endovascular thrombolysis or thrombectomy for cerebral venous thrombosis: study of Nationwide Inpatient Sample 2004–2014. *J Stroke Cerebrovasc Dis*. 2019;28:1440–1447. doi: 10.1016/j.jstrokecerebrovasdis.2019.03.025
 56. Xu Z, Li X, Feng D, Wang T, Xu X, Deng R, Zhou X, Chen G. Endovascular therapy versus anticoagulation for treatment of cerebral venous sinus thrombosis: a meta-analysis. *Neurologist*. 2021;27:69–73. doi: 10.1097/NRL.0000000000000369
 57. Naik A, Smith E, Dharnipragada R, Catapano JS, Cramer SW, Johnson R, Khanam R, Hassaneen W, Lawton MT, Arnold PM. Endovascular and medical management of cerebral venous thrombosis: a systematic review and network meta-analysis. *World Neurosurg*. 2022;165:e197–e205. doi: 10.1016/j.wneu.2022.05.142
 58. Siegler JE, Shu L, Yaghi S, Salehi Omran S, Elnazair M, Bakradze E, Psychogios M, De Marchis GM, Yu S, Klein P, et al. Endovascular therapy for cerebral vein thrombosis: a propensity-matched analysis of anticoagulation in the treatment of cerebral venous thrombosis. *Neurosurgery*. 2022;91:749–755. doi: 10.1227/neu.0000000000002098
 59. Paybast S, Mohamadian R, Emami A, Jameie M, Shahrab F, Zamani F, Sharifipour E. Safety and efficacy of endovascular thrombolysis in patients with acute cerebral venous sinus thrombosis: a systematic review [published online December 5, 2022]. *Interv Neuroradiol*. doi: 10.1177/15910199221143418. https://journals.sagepub.com/doi/10.1177/15910199221143418?url_ver=Z39.88-2003&rft_id=ori:rid:crossref.org&rft_dat=cr_pub%20%20pubmed
 60. Ferro JM, Bousser MG, Canhao P, Coutinho JM, Crassard I, Dentali F, di Minno M, Maino A, Martinelli I, Masuhr F, et al. European Stroke Organization guideline for the diagnosis and treatment of cerebral venous thrombosis. *Eur Stroke J*. 2017;2:195–221. doi: 10.1177/2396987317719364
 61. Mahale R, Mehta A, Varma RG, Hegde AS, Acharya PT, Srinivasa R. Decompressive surgery in malignant cerebral venous sinus thrombosis: what predicts its outcome? *J Thromb Thrombolysis*. 2017;43:530–539. doi: 10.1007/s11239-017-1489-x
 62. Misra S, Sudhir P, Nath M, Sharma VK, Vibha D. Decompressive surgery in cerebral venous thrombosis: a systematic review and meta-analysis. *Eur J Clin Invest*. 2023;53:e13944. doi: 10.1111/eci.13944
 63. Otite FO, Vanguru H, Anikpezie N, Patel SD, Chaturvedi S. Contemporary incidence and burden of cerebral venous sinus thrombosis in children of the United States. *Stroke*. 2022;53:e496–e499. doi: 10.1161/STROKEAHA.122.039822
 64. Kenet G, Kirkham F, Niederstadt T, Heinecke A, Saunders D, Stoll M, Brenner B, Bidlingmaier C, Heller C, Knofler R, et al. Risk factors for recurrent venous thromboembolism in the European collaborative paediatric database on cerebral venous thrombosis: a multicentre cohort study. *Lancet Neurol*. 2007;6:595–603. doi: 10.1016/S1474-4422(07)70131-X
 65. Christensen R, Krishnan P, deVeber G, Dlamini R, MacGregor D, Pulcine E, Moharir M. Cerebral venous sinus thrombosis in preterm infants. *Stroke*. 2022;53:2241–2248. doi: 10.1161/STROKEAHA.121.037621
 66. Moharir MD, Shroff M, Pontigon AM, Askalan R, Yau I, Macgregor D, Deveber GA. A prospective outcome study of neonatal cerebral sinovenous thrombosis. *J Child Neurol*. 2011;26:1137–1144. doi: 10.1177/0883073811408094
 67. Goldenberg NA, Kittelson JM, Abshire TC, Bonaca M, Casella JF, Dale RA, Halperin JL, Hamblin F, Kessler CM, Manco-Johnson MJ, et al. Effect of anticoagulant therapy for 6 weeks vs 3 months on recurrence and bleeding events in patients younger than 21 years of age with provoked venous thromboembolism: the Kids-DOTT randomized clinical trial. *JAMA*. 2022;327:129–137. doi: 10.1001/jama.2021.23182
 68. Connor P, Sanchez van Kammen M, Lensing AWA, Chalmers E, Kallay K, Hege K, Simioni P, Biss T, Bajolle F, Bonnet D, et al. Safety and efficacy of rivaroxaban in pediatric cerebral venous thrombosis (EINSTEIN-Jr CVT). *Blood Adv*. 2020;4:6250–6258. doi: 10.1182/bloodadvances.2020003244
 69. Mineyko A, Kirton A, Billingham L, Tatishvili NN, Wintermark M, deVeber G, Fox C, SIPS Investigators. Seizures and outcome one year after neonatal and childhood cerebral sinovenous thrombosis. *Pediatr Neurol*. 2020;105:21–26. doi: 10.1016/j.pediatrneurol.2019.08.012
 70. Sébire G, Tabarki B, Saunders DE, Leroy I, Liesner R, Saint-Martin C, Husson B, Williams AN, Wade A, Kirkham FJ. Cerebral venous sinus thrombosis in children: risk factors, presentation, diagnosis and outcome. *Brain*. 2005;128:477–489. doi: 10.1093/brain/awh412

71. Coutinho JM, Ferro JM, Canhao P, Barinagarrementeria F, Cantu C, Bousser MG, Stam J. Cerebral venous and sinus thrombosis in women. *Stroke*. 2009;40:2356–2361. doi: 10.1161/STROKEAHA.108.543884
72. Fang T, Shu L, Elnazeir M, Zubair AS, Kasab SA, Antonenko K, Heldner MR, Yaghi S, Henninger N; ACTION-CVT Study Collaborators. Characteristics and outcomes of postpartum cerebral venous sinus thrombosis: a subgroup analysis of the ACTION-CVT study. *J Stroke Cerebrovasc Dis*. 2022;31:106865. doi: 10.1016/j.jstrokecerebrovasdis.2022.106865
73. Kamel H, Navi BB, Sriram N, Hovsepian DA, Devereux RB, Elkind MSV. Risk of a thrombotic event after the 6-week postpartum period. *N Engl J Med*. 2014;370:1307–1315. doi: 10.1056/NEJMoa1311485
74. Aguiar de Sousa D, Canhão P, Ferro JM. Safety of pregnancy after cerebral venous thrombosis: systematic review update. *J Neurol*. 2018;265:211–212. doi: 10.1007/s00415-017-8666-x
75. Aguiar de Sousa D, Canhão P, Ferro JM. Safety of pregnancy after cerebral venous thrombosis: a systematic review. *Stroke*. 2016;47:713–718. doi: 10.1161/strokeaha.115.011955
76. Furie KL, Cushman M, Elkind MSV, Lyden PD, Saposnik G; on behalf of the American Heart Association/American Stroke Association Stroke Council Leadership. Diagnosis and management of cerebral venous sinus thrombosis with vaccine-induced immune thrombotic thrombocytopenia. *Stroke*. 2021;52:2478–2482. doi: 10.1161/STROKEAHA.121.035564
77. Schultz NH, Sørvoll IH, Michelsen AE, Munthe LA, Lund-Johansen F, Ahlen MT, Wiedmann M, Aamodt A-H, Skattør TH, Tjønnfjord GE, et al. Thrombosis and thrombocytopenia after ChAdOx1 nCoV-19 vaccination. *N Engl J Med*. 2021;384:2124–2130. doi: 10.1056/NEJMoa2104882
78. Greinacher A, Thiele T, Warkentin TE, Weisser K, Kyrle PA, Eichinger S. Thrombotic thrombocytopenia after ChAdOx1 nCov-19 vaccination. *N Engl J Med*. 2021;384:2092–2101. doi: 10.1056/NEJMoa2104840
79. Marchandot B, Carmona A, Trimaille A, Curtiaud A, Morel O. Procoagulant microparticles: a possible link between vaccine-induced immune thrombocytopenia (VITT) and cerebral sinus venous thrombosis. *J Thromb Thrombolysis*. 2021;52:689–691. doi: 10.1007/s11239-021-02505-4
80. Sharifian-Dorche M, Bahmanyar M, Sharifian-Dorche A, Mohammadi P, Nomovi M, Mowla A. Vaccine-induced immune thrombotic thrombocytopenia and cerebral venous sinus thrombosis post COVID-19 vaccination; a systematic review. *J Neurol Sci*. 2021;428:117607. doi: 10.1016/j.jns.2021.117607
81. Fan BE, Ling RR, Ramanathan K, Leung BPL, Lim XR, Chadachan VM, Thirugnanam U, Stegner D, Tu TM. COVID-19 mRNA vaccine-associated cerebral venous thrombosis: rare adverse event or coincidence? *Am J Hematol*. 2023;98:E4–E7. doi: 10.1002/ajh.26773
82. Sanchez van Kammen M, Aguiar de Sousa D, Poli S, Cordonnier C, Heldner MR, van de Munckhof A, Krzywicka K, van Haaps T, Ciccone A, Middeldorp S, et al. Characteristics and outcomes of patients with cerebral venous sinus thrombosis in SARS-CoV-2 vaccine-induced immune thrombotic thrombocytopenia. *JAMA Neurol*. 2021;78:1314–1323. doi: 10.1001/jamaneurol.2021.3619
83. van de Munckhof A, Lindgren E, Kleinig TJ, Field TS, Cordonnier C, Krzywicka K, Poli S, Sanchez van Kammen M, Borhani-Haghighi A, Lemmens R, et al. Outcomes of cerebral venous thrombosis due to vaccine-induced immune thrombotic thrombocytopenia after the acute phase. *Stroke*. 2022;53:3206–3210. doi: 10.1161/STROKEAHA.122.039575
84. Park J, Park MS, Kim HJ, Song TJ. Association of cerebral venous thrombosis with mRNA COVID-19 vaccines: a disproportionality analysis of the World Health Organization pharmacovigilance database. *Vaccines (Basel)*. 2022;10:799. doi: 10.3390/vaccines10050799
85. Rizk JG, Gupta A, Sardar P, Henry BM, Lewin JC, Lippi G, Lavie CJ. Clinical characteristics and pharmacological management of COVID-19 vaccine-induced immune thrombotic thrombocytopenia with cerebral venous sinus thrombosis: a review. *JAMA Cardiol*. 2021;6:1451–1460. doi: 10.1001/jamacardio.2021.3444



Stroke